| CASE REPORT |

https://doi.org/10.46419/cvj.57.6.2

Chronic Basophilic Leukemia with Thrombocytosis Treated with High-Dose Melphalan Pulses in a Canine Patient

P. J. Morales Orozco*
P. N. Reséndiz Alvarado
A. E. Magaña Anzaldo
D. B. Bernal Muñoz
A. G. Saavedra Ruvalcaba
P. J. Rosales Camacho
E. G. Pinedo Pesqueda

Abstract

Myeloproliferative disorders are neoplastic diseases characterized by excessive proliferation and maturation of hematopoietic cells. These disorders may involve multiple hematopoietic lineages or a single lineage. Treatment typically consists of supportive care and antineoplastic agents, most commonly antimetabolites. Chronic basophilic leukemia is a rare myeloproliferative disorder involving the basophilic lineage, and is frequently associated with basophilia and thrombocytosis in canine patients. Therefore, differentiation from essential thrombocythemia is critical. Essential thrombocythemia is also a myeloproliferative disorder characterized by clonal platelet overproduction independent of growth factors. Only a limited number of cases of chronic basophilic leukemia with thrombocytosis have been reported in dogs. Additional case reports and diagnostic investigations are required to better characterize this condition. This report describes a canine patient diagnosed with chronic basophilic leukemia and thrombocytosis that was successfully treated with high-dose melphalan pulse therapy .

Keywords: ***dog; chronic basophilic leukemia; thrombocytosis; neoplasia.***

Introduction

Chronic basophilic aleukemia is an extremely rare hematologic malignancy (Çehreli, 2018) in both human and veterinary medicine. It is characterized by excessive proliferation of basophils (Mears et al., 1997) and is considered a variant of chronic myeloid leukemia (Mears et al.,1997). Laboratory diagnostic criteria include fewer than 20% blasts and at least 40% basophilic cells in peripheral blood and/or bone marrow (Valent et al., 2017). In dogs, diagnosis is primarily based on morphological evalua-

Pablo José MORALES OROZCO[1] (corresponding author), veterinariamoro@gmail.com orcid.org/ 0009-0002-5051-0749; Paulina Naomi RESÉNDIZ ALVARADO[2], presendizalvarado.2b@gmail.com, orcid.org/0009-0001-5260-8750; Aida Evelyn MAGAÑA ANZALDO[1], aida.evelyn23@gmail.com, orcid.org/0009-0005-7217-4645; Diana Betsabé BERNAL MUÑOZ[2], diana.b.udg@gmail.com, orcid.org/0009-0001-8173-7893; Adolfo Giovanni SAAVEDRA RUVALCABA[3], adolfo.giovanni@outlook.com, orcid.org/0009-0003-1940-9738; Paulina Jocelyn ROSALES CAMACHO[4], paulina.rc999@gmail.con, orcid.org/0009-0004-8557-2127; Estefany Guadalupe PINEDO PESQUEDA[2], fanypinedo99@gmail.com, orcid.org/0009-0006-6934-0902.

[1]Laboratory and Clinic, Veterinary Hematology GDL, Avila Camacho 3017-7 Guadalajara México
[2]Veterinary Hematology GDL, Avila Camacho 3017-7 Guadalajara México.
[3]Clinic and Surgery, Veterinary Hematology GDL, Avila Camacho 3017-7 Guadalajara México
[4]Blood banking and transfusion medicine, Laboratory and Clinic, Veterinary Hematology GDL, Avila Camacho 3017-7 Guadalajara México.

tion and cytochemical staining (Mears et al., 1997), while there are no clearly established immunohistochemical markers for this condition in veterinary patients (Azakami et al., 2019).

In human medicine, diagnostic criteria first require differentiation between neoplastic basophilic disorders and reactive hyperbasophilia, which is defined as the persistent presence of at least 1,000 basophils/μL (Valent et al., 2017). Although commonly associated with myeloproliferative disorders, hyperbasophilia does not always indicate neoplasia (Valent et al., 2017).

A diagnosis of chronic basophilic leukemia is established when hyperbasophilia accounts for at least 40% of nucleated cells in peripheral blood and/or bone marrow, accompanied by evidence of malignancy such as increased immature forms or dysplastic morphological features (Valent et al., 2017).

The most recent sections of the World Health Organization classification propose separating basophil-associated disorders into independent categories (Zhang et al., 2021), and distinguishing acute basophilic neoplastic processes between *de novo* cases and those secondary to chronic basophilic leukemia (Zhang et al., 2021) as cases of blast crisis arising from chronic processes have been reported in humans. These conditions may also present with thrombocytosis (Mears et al., 1977).

In humans, approximately 80% of patients with myeloproliferative disorders harboir mutations in the JAK2, CALR, and MPL genes (Tefferi et al., 2024). In veterinary medicine, JAK2 gene mutations have been reported in some patients with essential thrombocythemia, but there are no reports of such mutations in other myeloproliferative disorders.

Hydroxyurea, a drug with anti-tumour activity, is useful for the treatment of basophilic leukemia in humans and dogs (Kennedy and Yarbro, 1966; Mears et al., 1997). A previous study reported a remission of 21 months in a dog with basophilic leukemia, and chemotherapy with hydroxyurea was shown to resolve thrombocytosis (Mears et al., 1997). However, oral gavage studies in rats and dogs and a cardiovascular study in telemetered dogs showed that hydroxyurea produced hematopoietic, lymphoid, cardiovascular, and gastrointestinal toxicity with steep dose response curves (Morton et al., 2015). In dogs administered 50 mg/kg/day for 1 month, findings included decreased circulating erythrocytes, leukocytes, and platelets, increased bone marrow cellularity, and elevated creatine kinase activity. Cardiovascular findings in dogs consisted of decreased systolic BP, increased diastolic BP, and increased heart rate, and were consistent with increased formation of nitric oxide from hydroxyurea (Morton et al., 2015).
In human medicine, melphalan has also been used to treat various hematopoietic neoplastic disorders, including multiple myeloma, breast carcinoma, and polycythemia vera (Hauch et al., 1978). It has therefore been proposed that it may be useful in the treatment of myeloproliferative disorders (Hauch et al., 1978).

Nishihori et al. (2014) determined in their study that the use of high-dose melphalan has ufavorable effects in human patients with essential thrombocythemia. Hauch et al. (1978) reported that patients with chronic myeloid leukemia treated experimentally with melphalan exhibited normalization of white blood cell parameters, reduction in spleen size until it became non-palpable, and marked qualitative clinical improvement as reported by treated patients. The study included 24 patients, and of these, six achieved complete remission of the disease. Positive results have been reported for the use of high-dose melphalan administered in 21-day cycles compared with conventional daily dosing in canine patients (Fernández and Chon, 2018). This high-dose regimen is well tolerated, with minimal adverse effects, for the treatment of multiple myeloma (Fernández and Chon, 2018). Only four cases of this disease have been formally reported in dogs: Alroy (1972), Birgel et al. (1977), Mears et al. (1997) who also reported association with thrombocytosis, and Azakami et al. (2019). All of these cases were treated with hydroxyurea with good overall results.

To the extent of the authors' knowledge, this is the first reported case describing JAK2 gene sequencing in a canine myeloproliferative disorder other than essential thrombocythemia. Further, it is the first case report in veterinary medicine of the use of melphalan to treat a chronic basophilic aleukemia.

Case presentation

An 11-year-old male Shih Tzu dog was referred to a haematology service with a history of two blood transfusions due to severe anaemia, moderate leukocytosis with basophil predominance, and marked thrombocytosis. Multiple complete blood counts performed at external laboratories prior to referral are summarized in Table 1. Manual leukocyte differentials were not performed during this period. The patient was empirically treated with doxycycline (10 mg/kg, SID) and prednisolone (1 mg/kg, BID). Upon physical examination, the patient exhibited cachexia (body condition score 2/5) with marked generalized muscle wasting and prominent bony structure, pale mucous membranes, incoordination, and moderate splenomegaly. Heart rate was 120 bpm, respiratory rate 40 rpm, and rectal temperature 38.9°C. The patient presented four syncopes the week prior to consultation. Water intake was normal according the owners though food intake was decreased.

Figure 1. Blood smear of the canine patient showing thrombocytosis and two apparently normal basophils. (black arrow). Wright stain pH 6.8. magnification 60x.

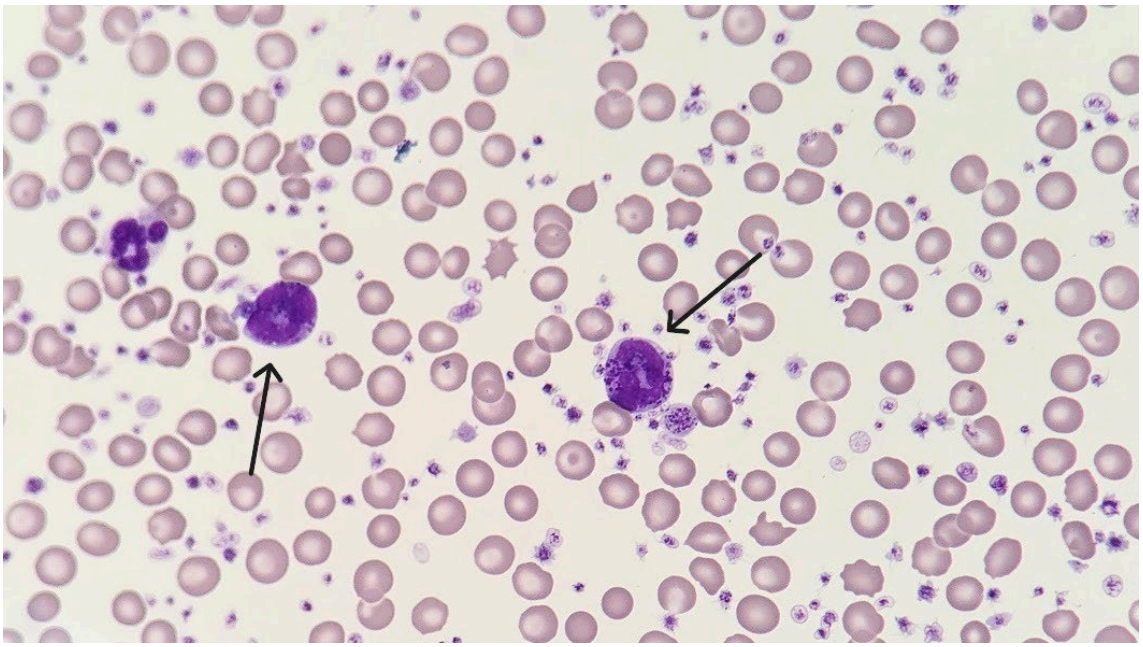

A complete automated blood count revealed mild non-regenerative anaemia, marked basophilic leukocytosis, and severe thrombocytosis (Table 1). Peripheral blood smear evaluation demonstrated severe thrombocytosis, while the majority of basophils were morphologically normal (Figure 1). Some hypolobulated basophils were also present.

Bone marrow aspiration and biopsy were performed. Cytologic evaluation revealed basophilic lineage hyperplasia comprising approximately 20% of nucleated marrow cells, with all stages of maturation present and moderate dysplastic changes (Figure 2). Megakaryocytic hyperplasia with numerous dwarf megakaryocytes was also observed (Figure 3). The blast percentage was mildly increased (5.4%), and erythroid precursors were markedly decreased, resulting in a myeloid-to-erythroid ratio of 6.31:1.

Figure 2. Microphotographs of the canine patient´s bone marrow showing promyelocytic basophils (black arrow), an aberrant mitosis (red arrow), and a gigantic myelocytic basophil (yellow arrow). Wright stain pH 6.8, magnification 100x.

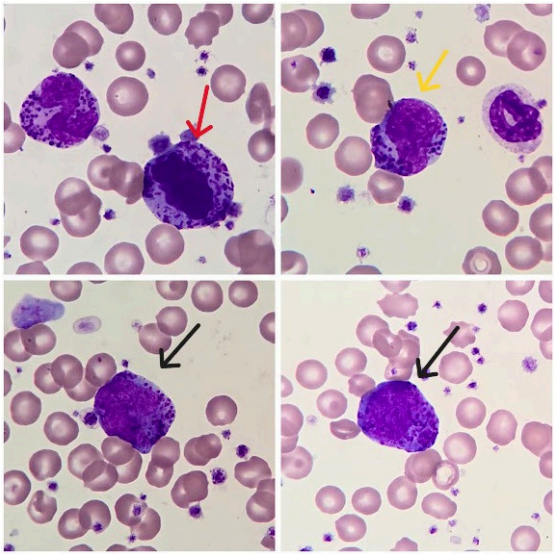

Figure 3. Images from a bone marrow cytology preparation, demonstrating several megakaryocytes with overt dysplastic changes. Red arrow: a small (dwarf) mature bilobed megakaryocyte with small platelet fields. Yellow arrow: a binucleate, vacuolated promegakaryocyte. Black arrow: a small unilobed megakaryocyte with mature platelet fields. Blue arrow: a small bilobed megakaryocyte with non-platelet pseudopodal projections. Wright stain pH 6.8, magnification 100x.

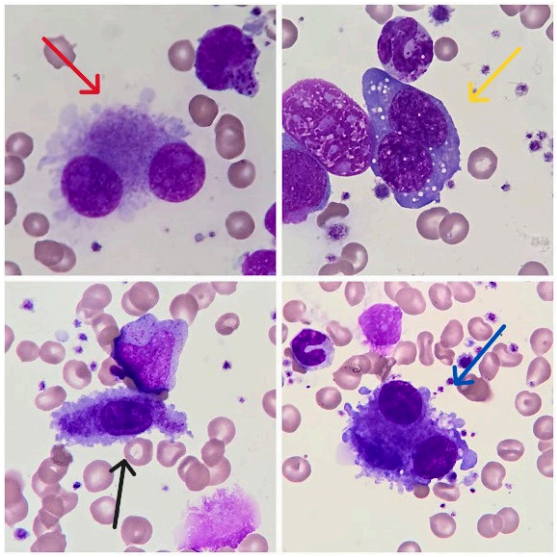

Figure 4. Granulocytic hyperplasia, primarily due to a basophilic lineage, as well as megakaryocytic hyperplasia with evident dysplastic changes. These are characterized mainly by dwarf and hypolobulated megakaryocytes (Hematoxylin & Eosin stain, magnification 40x). The bone marrow, free of collagen and reticular fibres, is observed under reticulum staining (magnification 40x).

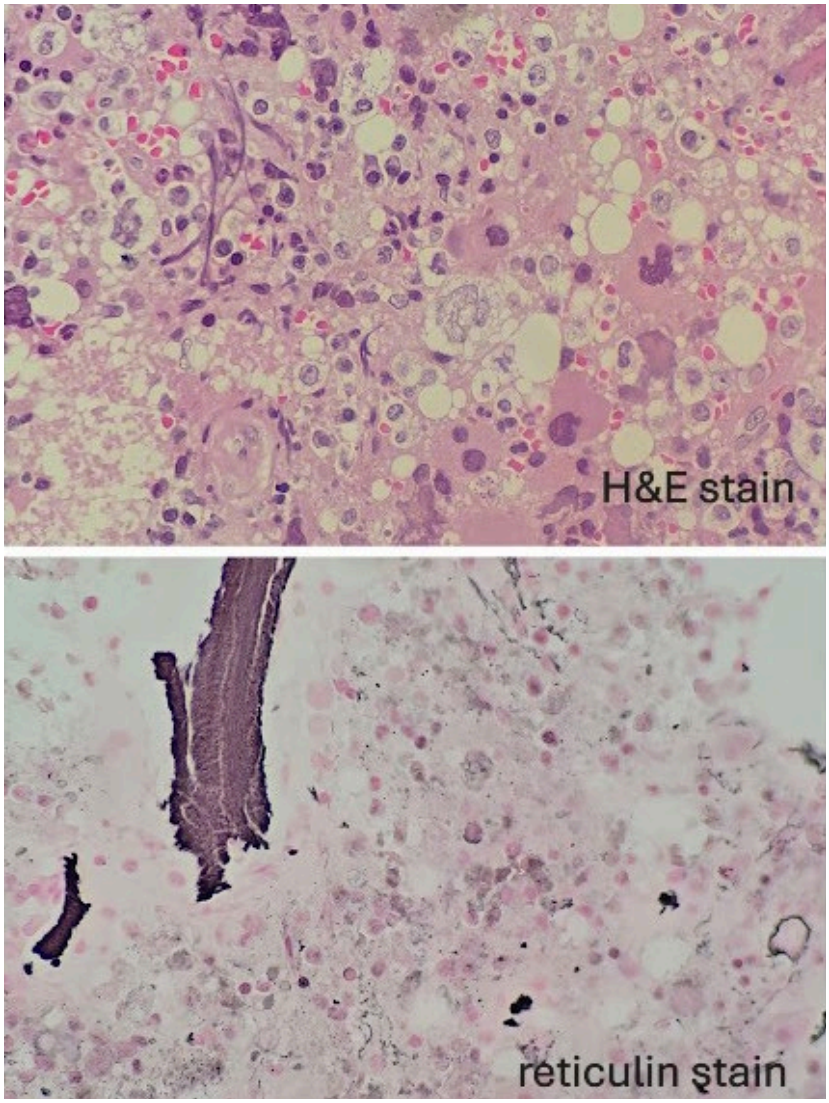

Differentiation of early-stage basophils from neoplastic mast cells and/or large granular lymphocytes was performed by morphological evaluation, maturation tendency and discharging the presence of mast cells or lymphoid neoplasia.

Histopathological examination demonstrated a hypercellular marrow with marked megakaryocytic hyperplasia and dysplasia, predominantly consisting of small, hypolobulated megakaryocytes. Increased basophilic and neutrophilic granulocytic lineages were observed, with no evidence of myelofibrosis on reticulin staining (Figure 4).

Treatment and follow up

Following the diagnosis of chronic basophilic leukemia, exploratory automated blood-based sequencing of the JAK2 gene was performed. This is a fundamental step of diagnosis in human medicine, and it also enables improving treatment and confirming a genetic base for the hyperproliferation of cells in this case. Four genetic variants were identified, including one variant of uncertain significance. These variants consisted principally in the transversion of adenine to thymine.

Due to the patient's history of severe persistent anaemia and the known myelosuppressive effects of hydroxyurea leading mainly to anaemia, an alternative antineoplastic agent was selected. High-dose melphalan pulse therapy was chosen based on previously reported protocols in veterinary oncology and previously success described in human medicine (Fernández and Chon, 2018). Comparison of two melphalan protocols and evaluation

Table 1. Overview of the canine patient's haematological values prior to consultation at the referral centre (blue), on the day of the consultation (black), and in the days prior to each melphalan cycle (brown).

DATE	RBC x10⁶	HCT %	HGB g/dL	WBC x10³/µL	NEU x10³/µL	LYMP x10³/µL	MON x10³/µL	BASO x10³/µL	EOS x10³/µL	PLT x10³/µL
06/06/2025	4.7	27.3	7.6	38.60	10.30	2.20	2.50	19.45	0.35	1 224
06/17/2025	2.80	16.2	7.6	18.00	13.40	2.5	2.00	2.10	0.25	1 732
PT 06/21/2025	4.8	30	11.0	23.10	9.20	4.40	4.19	5.10	0.25	1 924
06/24/2025	4.57	28.6	11.0	18.39	10.56	2.16	1.16	4.20	0.31	1 762
06/28/2025	4.41	27.4	10.2	24.44	9.83	2.06	2.10	10.20	0.25	1 762
07/05/2025	3.20	20.0	9.3	27.11	12.65	2.97	3.20	8.01	0.28	2 500
PT 07/23/2025	4.1	27	8.8	68 954	20.79	13.86	6.32	27.98	0.86	1 447
08/27/2025	4.40	26.6	10.6	10.24	5.83	1.77	2.05	0.51	0.09	1 335
09/23/2025	5.0	32	10.6	11.1	4.9	2.7	1.9	1.1	0.6	650
10/18/2025	5.15	30.7	11.3	9.31	2.56	3.51	1.76	1.01	0.45	1 036
12/10/2025	5.20	34	11.2	10.32	5.90	1.9	2.0	0.40	0.20	630
02/05/2026	5.39	35	12.8	14.61	9.82	1.47	1.82	0.68	0.83	1356
04/03/2026	6.0	41	14	15.7	10.00	1.4	3.6	0.0	0.6	320

RBC (red blood cells), HCT (heamatocrit), HGB (haemoglobin), WBC (white blood cells), NEU (neutrophils), LYMP (lymphocytes), MON (monocytes), BASO (basophils), EOS (eosinophils), PLT (platelets). PT (post-transfusion value).

of outcome and prognostic factors in multiple myeloma in dogs is described by Hauch et al., (1978).

Melphalan was administered at a dose of 7 mg/m² once daily for five consecutive days every 21 days. A complete blood count was performed prior to each treatment cycle. The first cycle was initiated without a new baseline blood count, using the results obtained at referral as the reference values. At the time of the last follow-up, the owners reported no clinical signs and an overall good quality of life. No recent haematology data were available for the most recent treatment cycle.

Discussion

Morphological dysplastic changes may be observed in both peripheral blood and bone marrow, highlighting the importance of careful microscopic evaluation, as automated analyzers may produce inaccurate results in cases with aberrant cell morphology (Çehreli et al., 2018). Clinical signs are variable and nonspecific and are often related to anaemia. Prompt bone marrow evaluation is therefore essential for appropriate diagnosis and therapeutic decision-making.

Differentiation between reactive hyperbasophilia and neoplastic basophilic disorders is critical but often challenging. Causes of hyperbasophilia are often related as a reactive process of other diseases, from this perspective it is fundamental to differentiate a reactive process from a neoplastic process to establish the correct treatment. In human medicine, genetic testing is routinely used to guide diagnosis and therapy, and similar approaches should be more widely adopted in veterinary oncology to individualize therapies and obtain better outcomes.

In this case, high-dose melphalan pulse therapy resulted in a favorable clinical response without significant adverse effects. This response may be related to underlying JAK2 alterations or other uncharacterized genetic abnormalities.

Conclusion

This report contributes to the growing body of evidence supporting alternative therapeutic approaches with fewer adverse effects for the management of myeloproliferative disorders in veterinary patients.

> References

- ALROY, J. (1972): Basophilic leukemia in a dog. Veterinary Pathology. 9 (2), 90-95. 10.1177/030098587200900201.
- AZAKAMI, D., A. SAITO, K. OCHIAI, T. ISHIWATA, K. TAKAHASHI, N. KAJI and M. MICHISHITA (2019): Chronic basophilic leukemia in a dog. Journal of Comparative Pathology. 166, 5-8. 10.1016/j.jcpa.2018.10.170.
- BIRGEL, E. I., and L. G. ROSENFELD (1977). A case of basophil leukemia in a dog and its differentiation from a case of disseminated malignant mastocytoma. Rev. Fac. Med. Vet. Zootec. Univ. S. Paulo. 14 , 31-36.
- ÇEHRELI, C. (2018): Diagnostic problems in chronic basophilic leukemia. Turkish Journal of Hematology. 35, 283. 10.4274/tjh.2018.0129.
- FERNÁNDEZ, R. and E. CHON (2018). Comparison of two melphalan protocols and evaluation of outcome and prognostic factors in multiple myeloma in dogs. Journal of Veterinary Internal Medicine. 32, 1060-1069. 10.1111/jvim.15084.
- HAUCH, T., G. LOGUE, J. LASZLO, E. COX, and W. RUNDLES (1978): Treatment of chronic granulocytic leukemia with melphalan. American Society of Hematology. PMID: 272928.
- KENNEDY, B. J. and J. W. YABRO (1966). Metabolic and therapeutic effects of hydroxyurea in chronic myeloid leukemia. JAMA, 195, 1038-1043.
- MEARS, E. A., R. E. RASKIN and A. M. LEGENDRE (1997): Basophilic leukemia in a dog. Journal of Veterinary Internal Medicine. 11, 92-94. 10.1111/j.1939-1676.1997.tb00079.x.
- MIZUKOSHI, T., Y. FUJINO, K. YASUKAWA, H. MATUMOTO, S. MATSUMURA, T. NAGASAKI, K. OHNO, H. TSUJIMOTHO and T. SHIMODA (2006): Essential thrombocythemia in a dog. Journal of Veterinary Medical Science. 68, 1203-1206. 10.1292/jvms.68.1203.
- MORTON, D., L. REED, W. HUANG, J. M. MARCEK, R. AUSTIN-LAFRANCE, C. A. NORTHCOTT, S. H. SCHELLING, B. E. ENERSON and L. TOMLINSON (2015): Toxicity of hydroxyurea in rats and dogs. Toxicologic pathology. 43, 498-512. 10.1177/0192623314559103.
- NISHIHORI, T., Y. HASSOUN, L. ZHANG, K. SHAIN, M. ALSINA and M. A. KHARFAN-DABAJA (2014): High-dose melphalan produces favorable response in a patient with multiple myeloma and coexisting essential thrombocythemia with JAK2 mutation. Bone marrow transplantation. 49, 148-149. 10.1038/bmt.2013.117.
- TEFFERI, A., A. M. VANNUCCHI and T. BARBUI (2024): Essential thrombocythemia: 2024 update on diagnosis, risk stratification, and management. American Journal of Hematology. 99, 697-718. 10.1002/ajh.27216.
- VALENT, P., K. SOTLAR, K. BLATT, K. HARTMANN, A. REITER, I. SADOVNIK, W. R. SPERR, P. BETTELHEIM, C. AKIN, K. BAUER, T. I. GEORGE, E. HADŽIJUSUFOVIĆ, D. WOLF, J. GOTLIB, F. X. MAHON, D. D. MATCALFE, H. P. NAPALJENI and M. AROCK (2017). Proposed diagnostic criteria and classification of basophilic leukemias and related disorders. Leukemia, 31, 788-797. 10.1038/leu.2017.15.
- ZHANG, Y., X. KANG, X CHEN and T. LI (2021): Acute basophilic leukemia arising from chronic myeloid leukemia with isolated thrombocytosis. Turkish Journal of Hematology. 38, 341. 10.4274/tjh.galenos.2021.2021.0546.

> Kronična bazofilna leukemija s trombocitozom liječenja visokim dozama melfalana u pasa

Pablo José MORALES OROZCO[1] (dopisni autor), veterinariamoro@gmail.com orcid.org/ 0009-0002-5051-0749; Paulina Naomi RESÉNDIZ ALVARADO[2], presendizalvarado.2b@gmail.com, orcid.org/0009-0001-5260-8750; Aida Evelyn MAGAÑA ANZALDO[1], aida.evelyn23@gmail.com, orcid.org/0009-0005-7217-4645; Diana Betsabé BERNAL MUÑOZ[2], diana.b.udg@gmail.com, orcid.org/0009-0001-8173-7893; Adolfo Giovanni SAAVEDRA RUVALCABA[3], adolfo.giovanni@outlook.com, orcid.org/0009-0003-1940-9738; Paulina Jocelyn ROSALES CAMACHO[4], paulina.rc999@gmail.con, orcid.org/0009-0004-8557-2127; Estefany Guadalupe PINEDO PESQUEDA[2], fanypinedo99@gmail.com, orcid.org/0009-0006-6934-0902. [1]Laboratory and Clinic, Veterinary Hematology GDL, Avila Camacho 3017-7 Guadalajara México [2]Veterinary Hematology GDL, Avila Camacho 3017-7 Guadalajara México.
[3]Clinic and Surgery, Veterinary Hematology GDL, Avila Camacho 3017-7 Guadalajara México
[4]Blood banking and transfusion medicine, Laboratory and Clinic, Veterinary Hematology GDL, Avila Camacho 3017-7 Guadalajara México.

Mijeloproliferativni poremećaji su neoplastične bolesti karakterizirane prekomjernom proliferacijom i sazrijevanjem hematopoetskih stanica. Ovi poremećaji mogu zahvaćati jednu ili više hematopoetskih loza. Liječenje se provodi potpornom terapijom i antineoplastičnim lijekovima, najčešće antimetabolitima. Kronična bazofilna leukemija rijedak je mijeloproliferativni poremećaj koji zahvaća bazofilnu lozu i često je povezan s bazofilijom i trombocitozom u pasa. Razlikovanje bazofilne leukemije od esencijalne trombocitemije vrlo je značajno. Esencijalna trombocitemija također je mijeloproliferativni poremećaj karakteriziran klonskom prekomjernom proizvodnjom trombocita neovisno o faktorima rasta. Kod pasa je dosad opisan mali broj slučajeva kronične bazofilne leukemije s trombocitozom. Potrebni su dodatni prikazi slučajeva i dijagnostička istraživanja kako bi se bolje okarakterizirala ova bolest. Ovaj prikaz slučaja opisuje psa kojem je dijagnosticirana kronična bazofilna leukemija i trombocitoza, a koji je uspješno liječen pulsnom terapijom visokim dozama melfalana.

Ključne riječi: *pas; kronična bazofilna leukemija; trombocitoza; neoplazija.*