| ORIGINAL SCIENTIFIC ARTICLE |

Comparing Immunohistochemistry, in situ Hybridization, and *in situ* Reverse Transcription PCR for Porcine Reproductive and Respiratory Syndrome Virus Detection

https://doi.org/10.46419/cvj.58.1.10

Received: 13 February 2026
Accepted: 14 July 2026
Online publication: 30 November 2026

D. Novosel
A. Jungić*
C. K. Hjulsager
R. Ocadiz-Delgado
E. Alvarez-Rios
P. Gariglio
L. E. Larsen

Abstract

Porcine reproductive and respiratory syndrome remains a significant challenge in swine health despite extensive research efforts. Traditional diagnostic methods, such as immunohistochemistry and *in situ* hybridization, are often limited in sensitivity due to the high genetic diversity of the virus. This study evaluates *in situ* reverse transcription PCR (IS-RT-PCR) as a more sensitive alternative for detecting low viral loads in formalin-fixed paraffin-embedded tissues. Through a comparative analysis of immunohistochemistry, *in situ* hybridization, and IS-RT-PCR, we determined that while immunohistochemistry offers rapid results at a lower cost, it failed to differentiate between viral genotypes. *In situ* hybridization provides slightly improved sensitivity compared to immunohistochemistry but is similarly hampered by the virus's genetic variability. In contrast, IS-RT-PCR demonstrated superior sensitivity and specificity, successfully detecting viral RNA even in samples that tested negative by the two traditional methods. These findings suggest that IS-RT-PCR is a valuable diagnostic tool for the precise detection and localisation of this syndrome in tissue samples, particularly in cases with low viral burden or ambiguous results from standard methods.

Key words: ***PRRSV; immunohistochemistry; in situ hybridization; in situ RT PCR; diagnostic.***

CC BY

Dinko NOVOSEL[1], novosel@veinst.hr, orcid.org/0000-0003-2602-8696; Andreja JUNGIĆ[2]*(corresponding author), jungic@veinst.hr, orcid.org/0000-0002-9497-9904; Charlotte Kristine HJULSAGER[3], CKHJ@ssi.dk, orcid.org/0000-0001-7557-8876; Rodolfo OCADIZ-DELGADO[4], wilox@cinvestav.mx, orcid.org/0000-0002-4576-881X; Elizabeth ALVAREZ-RIOS[4], elizabeth.alvarez@cinvestav.mx, orcid.org/0009-0004-4582-7762; Patricio GARIGLIO[4], vidal@cinvestav.mx, orcid.org/0000-0002-0024-7076; Lars Erik LARSEN[5], lael@sund.ku.dk, orcid.org/0000-0003-0730-5555.

[1]Laboratory for Pathology, Department of Pathology, Croatian Veterinary Institute, 10000 Zagreb, Croatia
[2]Laboratory for Rabies and General Virology, Department of Virology, Croatian Veterinary Institute, 10000 Zagreb, Croatia
[3]Virology and Microbiological Preparedness Statens Serum Institute, 2300 Copenhagen, Denmark
[4]Laboratory of Molecular Oncology, Department of Genetics and Molecular Biology; CINVESTAV-IPN, 07360 Ciudad de Mexico, Mexico
[5]Veterinary Clinical Microbiology, Department of Veterinary and Animal Sciences, University of Copenhagen, 1870 Frederiksberg C , Denmark

Introduction

For nearly four decades, porcine reproductive and respiratory syndrome (PRRS) has remained among the most economically significant swine diseases worldwide. Despite intensive research, many aspects of PRRS virus (PRRSV) pathogenesis remain unclear. The virus was first reported in North Carolina, Minnesota, and Iowa, USA (Loula, 1991; Keffaber, 1999) and subsequently isolated in Lelystad, the Netherlands (Terpstra et al., 1991; Wensvoort et al., 1991). It is classified within the *Arteriviridae* family (Plagemann and Moennig, 1992).

Typical gross pathological findings include lungs that fail to collapse, appearing red-mottled and firm. Microscopically, this manifests as multifocal interstitial pneumonia, characterized by type II pneumocyte hypertrophy and mixed mononuclear inflammatory cell infiltration (Rossow et al., 1994, 1995, 1996; Halbur et al., 1995, 1996). PRRSV replicates cytopathically, primarily in alveolar macrophages and pulmonary epithelial cells (Pol et al., 1991). During acute infection, viral load peaks in the lungs, making lung tissue a primary target for viral detection (Ait-Ali et al., 2007).

Immunohistochemistry (IHC) is routinely used to detect PRRSV in lung tissue because of its high specificity; however, it has only moderate sensitivity (Halbur et al., 1995). To mitigate false negatives, examination of at least five anteroventral lung sections on a single IHC slide is recommended (Yaeger, 2002). Although IHC provides valuable spatial context regarding antigen presence, *in situ* hybridization (ISH) is generally considered a superior tool for detecting viral nucleic acids, particularly at stages of lower viral load, thereby extending the detection window. Nevertheless, ISH has not been widely adopted because oligonucleotide probe design is difficult due to the high genetic diversity of PRRSV. Furthermore, ISH sensitivity is concentration-dependent, typically requiring tissue RNA concentrations exceeding 10^8 copies per 500 ng of nucleic acid.

Consequently, while ISH and IHC offer spatial resolution, they lack the sensitivity of polymerase chain reaction (PCR) methods, which can detect minute quantities of viral RNA. This discrepancy between the spatial advantages of *in situ* methods and the sensitivity of PCR presents a significant diagnostic challenge. Although ISH protocols can be optimized, they rarely achieve the sensitivity of PCR.

In situ PCR (IS-PCR), a technique introduced by Nuovo (2001), combines the sensitivity of PCR with the histological context of *in situ* hybridization. Despite its potential, it is rarely applied in veterinary medicine and, to our knowledge, has not yet been applied for PRRSV detection. The method involves amplification of specific target regions within the tissue, followed by detection of amplicons using labeled probes. A key advantage of *in situ* reverse transcriptase PCR (IS-RT-PCR) is its ability to detect low copy numbers of RNA while preserving tissue morphology. This novel, highly sensitive diagnostic tool could provide definitive confirmation of infection and offer new insights into PRRSV pathogenesis. The aim of the present study was to evaluate and compare three *in situ* methods (IHC, ISH, and IS-RT-PCR) for PRRSV detection.

Materials and methods

Case selection

For this study, 20 formalin-fixed paraffin-embedded (FFPE) blocks were selected, comprising eight lung, three lymph node, two ileum, and one kidney sample from pigs, and six pig fetal tissue samples (three lung, one myocardium, one lymph node, and one liver sample). One case included samples from multiple organs (lung, lymph node, ileum, and kidney) from the same animal. These samples were obtained from deceased pigs and aborted fetuses routinely submitted to the Croatian Veterinary Institute for health monitoring. Following post-mortem examination, tissue samples were fixed in 10% buffered formalin for 48 hours at 4°C, dehydrated through a graded ethanol series, cleared in xylene, and embedded in paraffin. All samples had previously tested positive for PRRSV by both IHC and conventional PCR. Sequencing of PCR products from selected positive samples confirmed all cases as PRRSV Type 1 (Subtype 1).

Immunohistochemistry (IHC)

Immunohistochemical labeling of the PRRSV antigen was performed using specific monoclonal antibodies against European and American strains of PRRSV ORF7 (clone 1AC7, IgG2a isotype, Ingenasa®, Spain) and anti-PRRSV nucleocapsid proteins specific for American and European types (clones 4A.5 and 6F.34, IgG2a isotype, JENO BIOTECH INC®, Korea), following previously described protocols (Halbur et al., 1994; Sorden et al., 1999). Tissue sections were deparaffinized in xylene and rehydrated in graded ethanol. Endogenous peroxidase activity was blocked with 3% hydrogen peroxide in TBS. Antigen retrieval was performed enzymatically using four different proteases with the PROTOCOL Microprobe staining system (Fisher Scientific ® Waltham, Massachusetts, USA) at temperatures ranging from 37°C to 105°C, according to the protocols listed in Table 1. To prevent nonspecific binding, sections were blocked with 2% bovine serum albumin (BSA) in TBS for 1 hour. The primary antibody was diluted 1:200 in 2% BSA in TBS and incubated overnight at room

Table 1. Epitope demasking protocols.

	Name of pronase	Solution	Incubation
1.	Proteinase K[1]	40 µL Proteinase K 2 mL TBS (according to manufacturer's instructions)	3 min at RT[2]
2.	Protease XIV	0,05 g Protease XIV 50 mL TBS	8 min at 37°C, 6 min at 105°C
3.	Pepsin	0.15 g Pepsine 50 mL TBS pH 2	8 min at 37°C, 6 min at 105°C
4.	Trypsin	0,05 g CaCl2 0,05 g Trypsin 250 50 mL TBS adjust pH 7.8	10 min at 37°C, 6 min at 105°C

[1]Dako® Code S3004
[2]Room temperature

temperature. The reaction was visualized using a secondary anti-mouse antibody labeled with a polymer detection system (Dako Envision, Carpinteria, California,USA) and DAB chromogen. Slides were counterstained with Mayer's hematoxylin, dehydrated, and mounted with DPX.

Riboprobes for *in situ* hybridization (ISH)

Three non-overlapping DIG-labeled oligonucleotide probes (20 bp each) targeting the ORF7 region of PRRSV Type 1 were designed. The sequences were: Probe 1: 5'-DIG-CUggCCAUUCCCCAUUggAgC-3'; Probe 2: 5'-DIG-AUCgAUUgCAAgCAgAgggA-3'; and Probe 3: 5'-DIG-gCCUgUCCUCCCCUAggUUg-3'. These probes hybridize with encoding regions 14639–14661, 14816–14837, and 14714–14735 of the Lelystad virus (GenBank accession number AY588319), respectively.

In situ hybridization (ISH)

In situ hybridization for the detection of PRRSV RNA was performed using DIG-labelled oligonucleotide probes according to a previously described protocol (Rosell et al., 1999). Tissue sections (5 µm thick) were mounted on positively charged slides, deparaffinized, rehydrated, and washed three times in 1X Automation buffer. Hybridization was carried out using the PROTOCOL Microprobe Staining System (Fisher Scientific® Waltham, Massachusetts, USA). Enzymatic pretreatment involved incubation with 0.3% pepsin for 8 minutes at 37°C, followed by heating to 105°C for 6 minutes. Sections were then incubated in 100% formamide at 105°C for 5 minutes. A hybridization cocktail containing 0.33 nmol/mL of each probe (Probes 1, 2 and 3) for a total of 1 nmol/mL was used. Prior to hybridization, slides were incubated at 105°C for 5 minutes, followed by hybridization at 37°C for 60 minutes. Post-hybridization washes were performed in 0.5X SSC, 0.25X SSC, and finally in Buffer 1. Detection was achieved using an alkaline phosphatase-conjugated anti-digoxigenin antibody (incubated at 37°C for 1 hour) and NBT/BCIP stock solution (Roche, USA) for 20 minutes at 37°C. Sections were counterstained with Fast Green, dehydrated, mounted with DPX, and examined by light microscopy.

In situ reverse transcription PCR (IS-RT-PCR)

Direct IS-RT-PCR was performed on 5 µm tissue sections according to previously described protocols with minor modifications (Nuovo, 2001; Ocadiz-Delgado et al., 2008, 2009, 2012, 2021; Novosel et al., 2018, 2019). Briefly, dewaxed sections on DNase/RNase-free electro-charged slides were treated with 0.5 mg/mL Proteinase K at room temperature for 20 minutes (fetal tissue) or 30 minutes (other tissues). After digestion, tissues were treated with 1 U/sample DNase I (RNase-free, Roche, USA) for 24 hours at 37°C. Following extensive rinsing with DEPC-treated water, tissues were treated with 0.25% acetic anhydride and 0.1 M triethanolamine for 10 minutes, followed by 20% acetic acid for 3 minutes with gentle agitation. After washing and dehydration in absolute ethanol, reverse transcription was performed using SuperScript II reverse transcriptase (Invitrogen, Carlsbad, California, USA). The reaction mixture (total volume, 100 µL) contained 100 ng PRRSV-RT primer (Table 2), 10 mM of each dNTP, 5x first-strand buffer, 0.1 M DTT, 40 U recombinant ribonuclease inhibitor, and 100 U reverse transcriptase. Slides were incubated at 37°C for 2 hours in a humidified chamber. Following cDNA synthesis, direct *in situ* PCR was performed using specific primers listed in Table 2. The master mix contained digoxigenin-11-dUTP (Roche, USA). PCR conditions (Perkin Elmer system) were

Table 2. Primer sequences used for IS-RT-PCR (Oleksiewicz et al., 1998)

RT-PCR Type	Primer sequence	Primer specificity	RT-PCR product size
ORF 7	RT primer 5' TCG CCC TAA T 3'	All known PRRSV-types	
	Forward PCR primer 5' GCC CCT GCC CAT CAC G 3'		American-type PRRSV: 660 bp
	Reverse PCR primer 5' TCG CCC TAA TTG AAT AGG TGA 3'		European-type PRRSV: 637 bp

as follows: denaturation at 90°C for 5 minutes; 18 cycles of 95°C for 20 seconds, 57°C for 30 seconds, and 72°C for 30 seconds; and a final elongation at 72°C for 5 minutes.

Detection of *in situ* PCR products

PCR products were detected using an indirect immunolabeling method. Slides were blocked with 5% BSA (Sigma, St. Louis, Missouri, USA) in PBS for 30 minutes at room temperature. An anti-DIG antibody (Fab fragments, alkaline phosphatase-conjugated; Roche, Indianapolis, Indiana, USA), diluted 1:200 in 100 mM Tris-HCl (pH 7.4) / 150 mM NaCl was applied (100 µL per sample) for 2 hours at room temperature. Slides were washed in 100 mM Tris-HCl (pH 7.4) / 150 mM NaCl / 0.1% Tween 20, then incubated in detection buffer (100 mM Tris-HCl pH 9.5, 150 mM NaCl) for 15 minutes. Visualization was performed with NBT/BCIP stock solution (Roche, USA) for 10–25 minutes. Finally, slides were counterstained with Fast Green, washed, dehydrated, and mounted with DPX.

Visualization and annotation of *in situ* methods

All IHC, ISH, and IS-RT-PCR micrographs were digitally processed using QuPath software. Positive signals were annotated and visualized using red RGB color (204, 51, 102), while negative areas were designated with RGB (51, 102, 204). Quantitative data on total and positive cell counts are presented in the corresponding figure legends.

Results

Sensitivity comparison

A total of 20 paraffin blocks were examined. Eighteen cases had previously been confirmed as PRRSV-positive by conventional PCR, while two were negative.

Comparison of the three *in situ* methods revealed significant differences in sensitivity (Table 3), which was lowest for IHC, detecting viral antigen in only 5 of 18 (27.7%) PCR-positive samples (three lungs and two lymph nodes). No fetal tissues tested positive by IHC. ISH demonstrated slightly higher sensitivity, detecting viral RNA in 8 of 18 (44.4%) samples, including ileum sections, but also failed to detect the virus in fetal tissues. In contrast, IS-RT-PCR showed significantly higher sensitivity, detecting viral RNA in 11 of 18 (61.1%) cases: four lungs, three lymph nodes, two ileums, one kidney, and notably, one fetal liver sample. All samples negative by conventional PCR were consistently negative across all three *in situ* methods.

Optimization of IHC pretreatment

To optimize the IHC protocol, four different protease pretreatments and three monoclonal antibodies (mAb) were tested on lung tissue (ID 311-11). Pretreatment with proteinase K and pepsin resulted in moderate tissue destruction (Figure 2B, 2C), whereas protease 14 and trypsin preserved tissue morphology well (Figure 2A, 2D). Despite the tissue damage, the strongest signal was achieved with proteinase K (positive in 5/18 samples). Protease 14 and trypsin detected the virus in 3/18 samples, while pepsin was the least effective (2/18). Quantitative analysis using QuPath confirmed these findings: Protease 14 yielded the highest percentage of positive signals (5.3%), followed closely by trypsin (4.8%) and proteinase K (4.2%), while pepsin was significantly lower (0.3%). Regarding the antibodies, the Ingenasa and JBT clones specific for Subtype 2 reacted similarly, while the JBT mAb specific for Subtype 1 was positive in only one case (Table 3).

Signal specificity

IHC

The IHC signal was strictly localized to the cytoplasm of alveolar macrophages within alveolar walls, interstitial spaces, and inflammatory foci (Figure 1B). Positive macrophages displayed varying degrees of apoptosis. In cells with extensive apoptosis, the signal was distributed throughout

Table 3. Results of tests using three *in situ* methods.

ID tissue	organ	PCR		Immunohystochemistry						*In situ* hybridisation	*In situ* RT PCR
				Pretreatement (Antibody)							
		PCR	Sequenced	Pep[1] (Ing[5])	Try[2] (Ing[5])	14[3] (Ing[5])	14[3] (US[6])	14[3] (EU[7])	K[4] (Ing[5])	All probes (3 nmol each)	
304-11	lung	+	yes	-	+	+	+	-	+	+	+
770-09-3	lung	+	yes	-	-	-	-	-	-	-	-
626-08-1	lung	+	yes	-	-	-	-	-	-	-	-
175-07-27	lung	+	yes	-	-	-	-	-	-	-	+
15-10	lung	+	no	-	+	-	-	-	-	+	+
304-11	lymph node	+	yes	-	-	-	-	-	-	+	+
792-07	lung	-	no	-	-	-	-	-	-	-	-
2188-12	lymph node	+	no	-	-	-	-	-	+	+	+
304-11	ileum	+	yes	-	-	-	-	-	-	+	+
2188-11	ileum	+	no	-	-	-	-	-	-	+	+
2105-09-2	lung	-	no	-	-	-	-	-	-	-	-
311-11	lung	+	yes	+	+	+	+	+	+	+	+
311-11	lymph node	+	yes	-	-	-	-	-	+	+	+
2188-12	kidney	+	no	-	-	-	-	-	-	-	+
126-07-5	fetal lymph node	+	yes	-	-	-	-	-	-	-	-
126-07-5	fetal lung	+	yes	-	-	-	-	-	-	-	-
126-07-5	fetal myocardium	+	yes	-	-	-	-	-	-	-	-
126-07-5	fetal lung	+	yes	-	-	-	-	-	-	-	-
126-07-5	fetal lung	+	yes	-	-	-	-	-	-	-	-
126-07-5	fetal liver	+	yes	-	-	-	-	-	-	-	+

[1] Pepsin; [2]Trypsine; [3]Protease 14; [4]Proteinase K; [5]IgG2a isotype, Ingenasa®, Madrid, Spain ; [6] clones 4A.5 IgG2a isotype, JENO BIOTECH INC®, Chuncheon, Korea ; [7] Clones 6F.34, IgG2a isotype, JENO BIOTECH INC®, Chuncheon Korea .

the cell, whereas in cells with intact nuclei, the signal was perinuclear. No signal was detected in pneumocytes or bronchial ciliated epithelial cells. In lymph nodes, sparse histiocytes in the medulla and cortex showed positivity.

ISH

As with IHC, the ISH signal was observed in alveolar macrophages in inflamed areas (Figure 1D). However, the frequency of positive cells was higher with ISH than with IHC (quantitative analysis: 8.6% vs 5.6% in lung tissue ID 311-11; Figure 1). The ISH signal was detected in both the cytoplasm and nuclei of macrophages. In the ileum, where IHC was negative, ISH clearly identified positive macrophages in proliferative areas (Figure 3H).

IS-RT-PCR

IS-RT-PCR produced the most intense and extensive staining (Figure 1F), significantly enhancing

Figure 1. Comparison of detection methods in lung tissue (ID 311-11). (A, B) IHC (Protease 14 pretreatment, Ingenasa Mab) showing positive signal in alveolar macrophages. (C, D) ISH showing slightly more frequent positive cells compared to IHC. (E, F) IS-RT-PCR showing the most intense and extensive staining. (A, C, E) 10X magnification with QuPath visualization analysis (red = positive signal). (B, D, F) 40X magnification showing cellular localization. Note the significant increase in sensitivity with IS-RT-PCR (27.7% positivity) compared with ISH (8.6%) and IHC (5.3%).

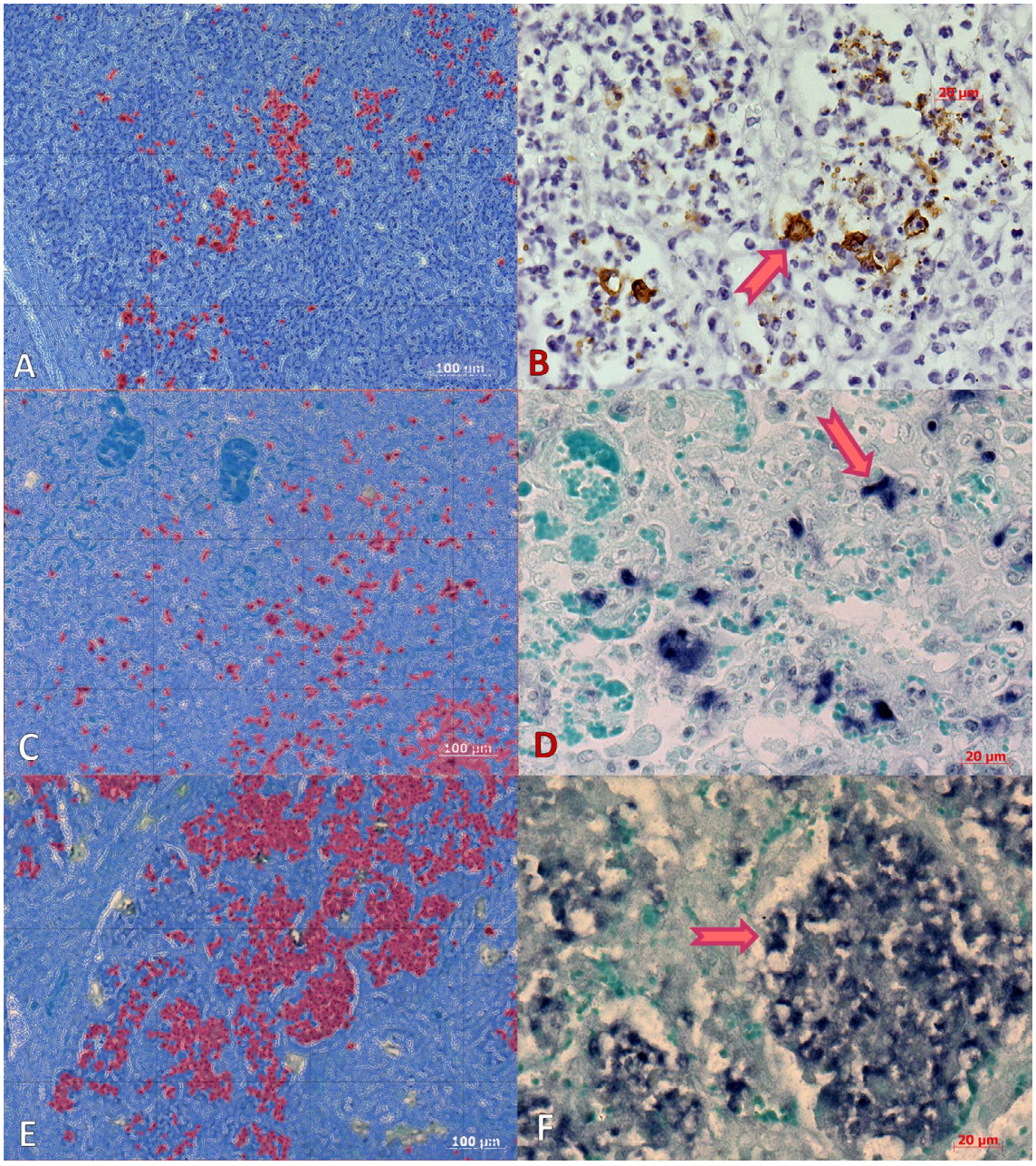

detection in tissues with low viral loads. Positive signals were identified in the lung, lymph nodes, ileum, kidney, and fetal liver. In the lungs, alveolar macrophages showed a robust signal in both the cytoplasm and nuclei (Figure 3C). Quantitative analysis of lung tissue (ID 311-11) showed 27.7% positivity, a marked increase compared with IHC and ISH (Figure 1E). In the ileum, strong staining was observed in submucosal lymphoid tissue, goblet cell cytoplasm, and enterocyte nuclei (Figure 3I). Notably, IS-RT-PCR was the only method that detected the virus in fetal tissue, specifically in hepatocytes surrounding a centrilobular degenerative zone in the liver (Figure 3C), where both IHC and ISH were negative.

Discussion

Accurate detection of PRRSV in tissue samples is critical for understanding viral pathogenesis and confirming diagnosis, particularly in cases with

Figure 2. Comparison of protease pretreatments for IHC in lung tissue (ID 311-11), at 40x magnification. (A) Protease 14; (B) Proteinase K, with moderate tissue destruction; (C) Pepsin; (D) Trypsin. (E-H) Corresponding QuPath analysis for each pretreatment (red = positive signal). Protease 14 and trypsin provided the best balance between signal intensity and tissue preservation.

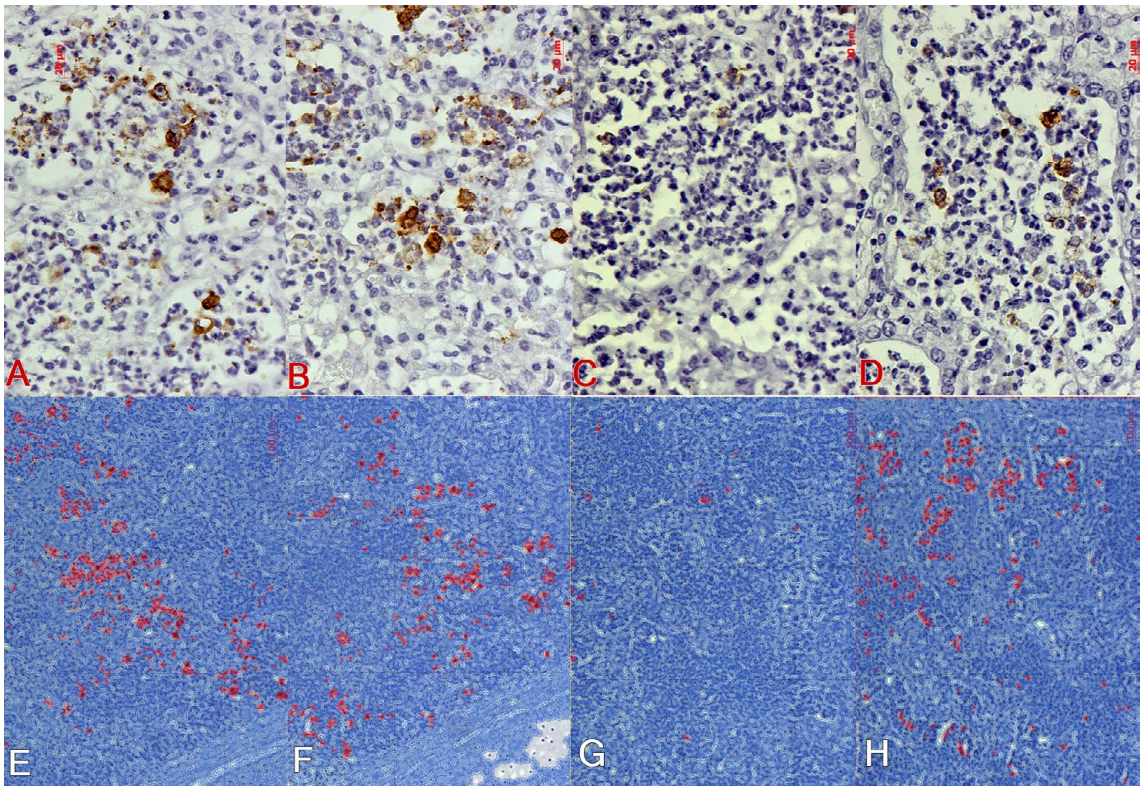

low viral loads. In this study, we compared the diagnostic performance of IHC, ISH, and IS-RT-PCR. Although IHC is a rapid and cost-effective method, our results confirm its limited sensitivity and inability to reliably distinguish between viral strains, consistent with previous reports (Halbur et al., 1995). Even though we tested strain-specific monoclonal antibodies, the antigen retrieval process, which is essential for breaking fixative-induced bonds (Sorden et al., 1999) altered epitope structures. This led to cross-reactivity or loss of specificity, indicating that IHC is suitable for general PRRSV detection but unreliable for genotyping. Regarding enzymatic pretreatment, we found that protease 14 and trypsin provided the optimal balance between antigen unmasking and tissue preservation, whereas proteinase K, despite yielding strong signals, caused excessive tissue digestion that compromised histopathological assessment.

Comparison between IHC and ISH showed that ISH has higher sensitivity (44.4% vs 27.7%), consistent with previous findings (Rosell et al., 1999). This is likely because ISH detects viral RNA, which can be present even when viral capsid proteins have not yet been synthesized or are present at levels below the IHC detection threshold. ISH signals were also observed in the nuclei of macrophages, suggesting the presence of replicative intermediates. However, ISH remains constrained by the high genetic diversity of PRRSV, as the method relies on precise probe-genome matching, so genetic drift can result in false-negative outcomes.

The most significant finding of this study is the superior performance of IS-RT-PCR, which demonstrated the highest sensitivity (61.1%) and specificity. By amplifying viral RNA directly within the tissue, using protocols adapted from Nuovo (2001) and specific primers described by Oleksiewicz et al. (1998), this method overcame the limitations of both IHC and ISH. Notably, IS-RT-PCR was the only method capable of detecting PRRSV in fetal liver tissue, specifically within Kupffer cells. These cells contained hemosiderin pigment, which can complicate IHC interpretation because it resembles DAB chromogen. However, the distinct staining pattern of IS-RT-PCR confirmed that these were infected macrophages phagocytosing erythrocytes. This observation provides valuable insight into vertical transmission and fetal pathogenesis, extending the descriptions by Rossow et al. (1996). Although technically more demanding than IHC, IS-RT-PCR is a powerful tool for confirming unclear cases and for research purposes where high sensitivity and preservation of morphological context are required.

Figure 3. Detection in fetal liver (ID 126-07-5) and ileum (ID 2188-11). (A-F) Fetal liver: IHC (A, D) and ISH (B, E) were negative. IS-RT-PCR (C, F) clearly detected viral RNA in Kupffer cells (arrows). Note: the golden-brown pigment in A, B, D and E is hemosiderin, not a positive signal. (G-I) Ileum: IHC (G) was negative, whereas ISH (H) and IS-RT-PCR (I) showed positive staining in lymphoid tissue and enterocytes.

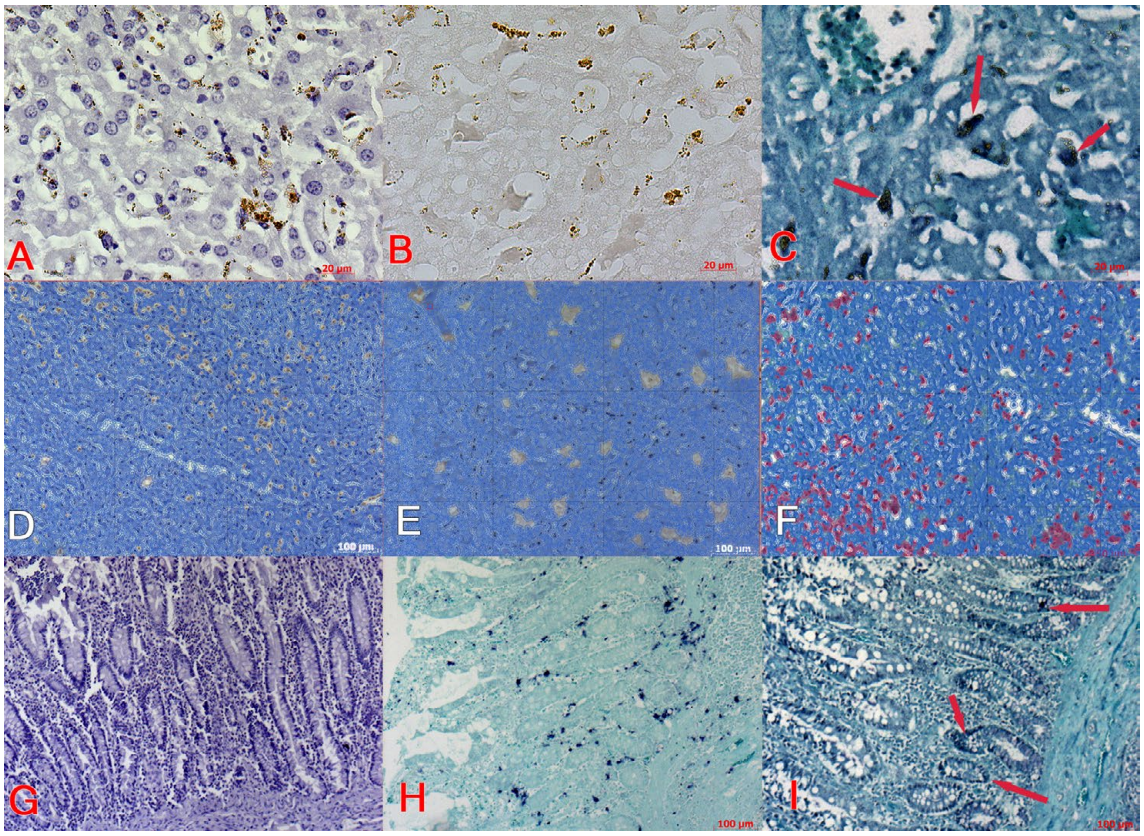

Conclusions

Immunohistochemistry (IHC) remains a valuable, rapid, and cost-effective tool for routine diagnosis, provided antigen retrieval protocols are carefully optimized for the specific tissue and enzyme used. However, because of epitope alteration during processing, IHC cannot be reliably used for PRRSV genotyping. *In situ* hybridization (ISH) offers improved sensitivity than IHC and extends the detection window to later stages of infection, yet its diagnostic accuracy is limited by the high genetic diversity of the virus.

The most significant finding of this study is the superiority of IS-RT-PCR. This method showed the highest sensitivity, successfully detecting viral RNA in fetal tissues in which both IHC and ISH failed. Although IS-RT-PCR approaches the sensitivity of standard *in vitro* PCR, it uniquely preserves tissue morphology, allowing for precise cellular localization of the virus. Consequently, while *in situ* methods generally do not replace high-throughput screening methods, IS-RT-PCR serves as a powerful "gold standard" for confirmatory diagnosis and research when histopathological context is required. All *in situ* findings should be interpreted by trained histopathologists in conjunction with clinical history and gross pathology.

Acknowledgments

This study was supported by COST Action FA0902 (Understanding and combating porcine reproductive and respiratory syndrome in Europe).

> References

- AIT-ALI, T., A. D. WILSON, D. G. WESTCOTT, M. CLAPPERTON, M. WATERFALL, M. A. MELLENCAMP, T. W. DREW, S. C. BISHOP, and A. L. ARCHIBALD (2007): Innate immune responses to replication of porcine reproductive and respiratory syndrome virus in isolated Swine alveolar macrophages. Viral Immunol. 20, 105–118. 10.1089/vim.2006.0078.
- HALBUR, P. G., J. J. ANDREWS, E. L. HUFFMAN, P. S. PAUL, X. J. MENG, and Y. NIYO (1994): Development of a streptavidin-biotin immunoperoxidase procedure for the detection of porcine reproductive and respiratory syndrome virus antigen in porcine lung. J. Vet. Diagn. Invest. 6, 254–257. 10.1177/104063879400600219.
- HALBUR, P. G., P. S. PAUL, M. L. FREY, J. LANDGRAF, K. EERNISSE, X. J. MENG, M. A. LUM, J. J. ANDREWS, and J. A. RATHJE (1995): Comparison of the pathogenicity of two US porcine reproductive and respiratory syndrome virus isolates with that of the Lelystad virus. Vet. Pathol. 32, 648–660. 10.1177/030098589503200606.
- HALBUR, P. G., P. S. PAUL, M. L. FREY, J. LANDGRAF, K. EERNISSE, X. J. MENG, J. J. ANDREWS, M. A. LUM, and J. A. RATHJE (1996): Comparison of the antigen distribution of two US porcine reproductive and respiratory syndrome virus isolates with that of the Lelystad virus. Vet. Pathol. 33, 159–170. 10.1177/030098589603300205.
- KEFFABER, K. K. (1999): Reproductive failure of unknown etiology. American Association of Swine Practitioners Newsletters. 1–10.
- LOULA, T. (1991): Mystery pig disease. Agri-Practice 12(1) 23–34.
- NOVOSEL, D., D. CADAR, T. TUBOLY, A. JUNGIC, T. STADEJEK, T. AIT-ALI, and A. CSAGOLA (2018): Investigating porcine parvoviruses genogroup 2 infection using in situ polymerase chain reaction. BMC Vet. Res. 14, 163. 10.1186/s12917-018-1487-z.
- NOVOSEL, D., T. TUBOLY, G. BALKA, L. SZEREDI, I. LOJKIC, A. JUNGIC, Z. ACINGER-ROGIC, T. AIT-ALI, and A. CSAGOLA (2019): Evidence of CPV2c introgression into Croatia and novel insights into phylogeny and cell tropism. Sci. Rep. 9, 16909. 10.1038/s41598-019-53422-9.
- NUOVO, G. J. (2001): Co-labeling using in situ PCR: a review. J. Histochem. Cytochem. 49, 1329–1339. 10.1177/002215540104901101.
- OCADIZ-DELGADO R., E. CASTAÑEDA-SAUCEDO, A. K. INDRA, R. HERNANDEZ-PANDO, P. FLORES-GUIZAR, J. L. CRUZ-COLIN, F. RECILLAS-TARGA, G. PEREZ-ISHIWARA, L. COVARRUBIAS, and P. GARIGLIO (2012): RXRα deletion and E6E7 oncogene expression are sufficient to induce cervical malignant lesions *in vivo*. Cancer Lett. 317, 226–236. 10.1016/j.canlet.2011.11.031.
- OCADIZ-DELGADO, R., J.-L. CRUZ-COLIN, E. ALVAREZ-RIOS, A. TORRES-CARRILLO, K. HERNANDEZ-MENDOZA, J.-C. CONDE-PÉREZPRINA, G.-I. DOMINGUEZ-GOMEZ, E. GARCIA-VILLA, P. F. LAMBERT, and P. GARIGLIO (2021): Expression of miR-34a and miR-15b during the progression of cervical cancer in a murine model expressing the HPV16 E7 oncoprotein. J. Physiol. Biochem. 77, 547–555. 10.1007/s13105-021-00818-9.
- OCADIZ-DELGADO, R., E. CASTANEDA-SAUCEDO, A. K. INDRA, R. HERNANDEZ-PANDO, and P. GARIGLIO (2008): Impaired cervical homeostasis upon selective ablation of RXRalpha in epithelial cells. Genesis. 46, 19–28. 10.1002/dvg.20357.
- OCADIZ-DELGADO, R., A. MARROQUIN-CHAVIRA, R. HERNANDEZ-MOTE, C. VALENCIA, M. E. MANJARREZ-ZAVALA, L. COVARRUBIAS, and P. GARIGLIO (2009): Induction of focal epithelial hyperplasia in tongue of young bk6-E6/E7 HPV16 transgenic mice. Transgenic Res. 18, 513–527. 10.1007/s11248-009-9243-6.
- OLEKSIEWICZ, M. B., A. BØTNER, K. G. MADSEN, and T. STORGAARD (1998): Sensitive detection and typing of porcine reproductive and respiratory syndrome virus by RT-PCR amplification of whole viral genes. Vet. Microbiol. 64, 7–22. 10.1016/s0378-1135(98)00254-5.
- PLAGEMANN, P. G., and V. MOENNIG (1992): Lactate dehydrogenase-elevating virus, equine arteritis virus, and simian hemorrhagic fever virus: a new group of positive-strand RNA viruses. Adv. Virus Res. 41, 99–192. 10.1016/s0065-3527(08)60036-6.
- POL, J. M., J. E. VAN DIJK, G. WENSVOORT, and C. TERPSTRA (1991): Pathological, ultrastructural, and immunohistochemical changes caused by Lelystad virus in experimentally induced infections of mystery swine disease (synonym: porcine epidemic abortion and respiratory syndrome (PEARS)). Vet. Q. 13, 137–143. 10.1080/01652176.1991.9694298
- ROSELL, C., J. SEGALÉS, J. PLANA-DURÁN, M. BALASCH, G. M. RODRÍGUEZ-ARRIOJA, S. KENNEDY, G. M. ALLAN, F. MCNEILLY, K. S. LATIMER, and M. DOMINGO (1999): Pathological, immunohistochemical, and in-situ hybridization studies of natural cases of postweaning multisystemic wasting syndrome (PMWS) in pigs. J. Comp. Pathol 120, 59–78. 10.1053/jcpa.1998.0258
- ROSSOW, K. D., J. E. COLLINS, S. M. GOYAL, E. A. NELSON, J. CHRISTOPHER-HENNINGS, and D. A. BENFIELD (1995): Pathogenesis of porcine reproductive and respiratory syndrome virus infection in gnotobiotic pigs. Vet. Pathol. 32, 361–373. 10.1177/030098589503200404
- ROSSOW, K. D., D. A. BENFIELD, S. M. GOYAL, E. A. NELSON, J. CHRISTOPHER-HENNINGS, and J. E. COLLINS (1996): Chronological immunohistochemical detection and localization of porcine reproductive and respiratory syndrome virus in gnotobiotic pigs. Vet. Pathol. 33, 551–556. 10.1177/030098589603300510
- ROSSOW, K. D., E. M. BAUTISTA, S. M. GOYAL, T. W. MOLITOR, M. P. MURTAUGH, R. B. MORRISON, D. A. BENFIELD, and J. E. COLLINS (1994): Experimental porcine reproductive and respiratory syndrome virus infection in one-, four-, and 10-week-old pigs. J. Vet. Diagn. Invest 6, 3–12. 10.1177/104063879400600102
- SORDEN, S. D., P. A. HARMS, P. NAWAGITGUL, D. CAVANAUGH, and P. S. PAUL (1999): Development of a polyclonal-antibody-based immunohistochemical method for the detection of type 2 porcine circovirus in formalin-fixed, paraffin-embedded tissue. J. Vet. Diagn. Invest. 11, 528–530. 10.1177/104063879901100607
- TERPSTRA, C., G. WENSVOORT, and J. M. POL (1991): Experimental reproduction of porcine epidemic abortion and respiratory syndrome (mystery swine disease) by infection with Lelystad virus: Koch's postulates fulfilled. Vet. Q. 13, 131–136. 10.1080/01652176.1991.9694297
- WENSVOORT, G., C. TERPSTRA, J. M. POL, E. A. TER LAAK, M. BLOEMRAAD, E. P. DE KLUYVER, C. KRAGTEN, L. VAN BUITEN, A. DEN BESTEN, and F. WAGENAAR (1991): Mystery swine disease in The Netherlands: the isolation of Lelystad virus. Vet. Q. 13, 121–130. 10.1080/01652176.1991.9694296
- YAEGER, M. J. (2002): The diagnostic sensitivity of immunohistochemistry for the detection of porcine reproductive and respiratory syndrome virus in the lung of vaccinated and unvaccinated swine. J. Vet. Diagn. Invest 14, 15–19. 10.1177/104063870201400104

> Usporedba imunohistokemije, hibridizacije in situ i PCR-a s reverznom transkripcijom *in situ* za detekciju virusa reproduktivnog i respiratornog sindroma svinja

Dinko NOVOSEL[1], novosel@veinst.hr, orcid.org/0000-0003-2602-8696; Andreja JUNGIĆ[2]*(dopisni autor), jungic@veinst.hr, orcid.org/0000-0002-9497-9904; Charlotte Kristine HJULSAGER[3], CKHJ@ssi.dk, orcid.org/0000-0001-7557-8876; Rodolfo OCADIZ-DELGADO[4], wilox@cinvestav.mx, orcid.org/0000-0002-4576-881X; Elizabeth ALVAREZ-RIOS[4], elizabeth.alvarez@cinvestav.mx, orcid.org/0009-0004-4582-7762; Patricio GARIGLIO[4], vidal@cinvestav.mx, orcid.org/0000-0002-0024-7076; Lars Erik LARSEN[5], lael@sund.ku.dk, orcid.org/0000-0003-0730-5555.

[1]Laboratorij za patologiju, Odjel za patološku morfologiju, Hrvatski veterinarski institut, 10000 Zagreb, Hrvatska
[2]Laboratorij za bjesnoću i opću virologiju, Odjel za virologiju, Hrvatski veterinarski institut, 10000 Zagreb, Hrvatska
[3]Virology and Microbiological Preparedness Statens Serum Institute, 2300 Copenhagen, Denmark
[4]Laboratory of Molecular Oncology, Department of Genetics and Molecular Biology, Centro de Investigación y de Estudios Avanzados del Instituto Politécnico Nacional (Cinvestav-IPN), 07360 Ciudad de Mexico, Mexico
[5]Veterinary Clinical Microbiology, Department of Veterinary and Animal Sciences, University of Copenhagen, Frederiksberg C 1870, Denmark

Reproduktivni i respiratorni sindrom svinja (PRRS) i dalje predstavlja značajan izazov za zdravlje svinja unatoč opsežnim istraživanjima. Tradicionalne dijagnostičke metode, poput imunohistokemije (IHC) i *in situ* hibridizacije (ISH), često imaju ograničenu osjetljivost zbog velike genetske raznolikosti virusa. Ovo istraživanje procjenjuje *in situ* lančanu reakciju polimeraze s prethodnom reverznom transkripcijom (IS-RT-PCR) kao osjetljiviju alternativu za detekciju niskih koncentracija virusa u tkivima fiksiranim u formalinu i uklopljenim u parafin (FFPE). Usporedna analiza IHC-a, ISH-a i IS-RT-PCR-a pokazala je da IHC, iako nudi brze rezultate uz niže troškove, ne omogućuje razlikovanje virusnih genotipova. ISH pruža neznatno bolju osjetljivost u usporedbi s IHC-om, no i dalje je ograničena genetskom varijabilnošću virusa. Nasuprot tome, IS-RT-PCR pokazuje superiornu osjetljivost i specifičnost te uspješno detektira virusnu RNK čak i u uzorcima koji su bili negativni pri testiranju IHC-om i ISH-om. Ovi rezultati ukazuju na to da je IS-RT-PCR vrijedan dijagnostički alat za preciznu detekciju i lokalizaciju PRRSV-a u tkivnim uzorcima, osobito u slučajevima s niskom koncentracijom virusa ili dvojbenim rezultatima standardnih metoda.

Ključne riječi: *PRRSV; imunohistokemija; in situ hibridizacija; in situ RT-PCR; dijagnostika*.