| CASE REPORT |

Gallbladder Rupture with Bile Peritonitis in a Cat: Clinical, Ultrasonographic and Surgical Findings

https://doi.org/10.46419/cvj.58.1.4

Received: 7 July 2026
Accepted: 19 August 2026
Online publication: 30 November 2026

Y. Park
A.-J. Lee
D.-H. Seo
H.-Y. Kim*

Abstract

Gallbladder rupture with bile peritonitis is uncommon in cats and may be difficult to diagnose when typical obstructive findings are absent. A 9-year-old spayed, female, domestic shorthair cat was referred for vomiting, lethargy, anorexia and fever. Initial examination revealed marked hepatocellular enzyme elevation without hyperbilirubinaemia, obvious common bile duct dilation or clinically meaningful abdominal effusion. Serial ultrasonography subsequently documented progressive ascites and peritonitis despite transient clinical and biochemical improvement. On day 12, abdominal fluid bilirubin was 159.1 µmol/L (9.3 mg/dL), compared with concurrent serum bilirubin of 22.2 µmol/L (1.3 mg/dL). Exploratory laparotomy on day 13 confirmed extensive gallbladder rupture and severe bile peritonitis. Cholecystectomy was performed after confirmation of extrahepatic biliary patency, followed by lavage and drainage. The cat survived to postoperative day 538. This case illustrates the value of serial ultrasonography, abdominal fluid analysis and operative source control with ambiguous initial findings of feline biliary leakage.

Key words: ***abdominal effusion; bile peritonitis; cholecystectomy; extrahepatic biliary disease; gallbladder rupture; ultrasonography.***

Introduction

Biliary tract disease in cats can be diagnostically challenging because clinical signs, serum biochemical abnormalities and ultrasonographic findings are often non-specific (Brain et al., 2006; Otte et al., 2017; Griffin, 2019). Gallbladder rupture with bile peritonitis requires timely source control, but the decision to operate is usually easier with the presence of marked hyperbilirubinemia, common bile duct dilation or direct ultrasonographic evidence of structural failure (Low and Williams, 2023). Published feline reports of biliary leakage and extrahepatic biliary surgery

CC BY

Yongwon PARK[1], spid19@naver.com, orcid.org/0009-0007-8194-1206; A-Jin LEE[2], orelieaj@gmail.com; Do-Hyun SEO[2], dodoseo1270@daum.net; Hwi-Yool KIM[3]* (corresponding author), hykim@konkuk.ac.kr, orcid.org/0000-0001-6237-9958.

[1]24Soom Animal Hospital, 16568 Suwon, Republic of Korea; Department of Veterinary Surgery, College of Veterinary Medicine, Konkuk University, 05029 Seoul, Republic of Korea
[2]24Soom Animal Hospital, 16568 Suwon, Republic of Korea;
[3]Department of Veterinary Surgery, College of Veterinary Medicine, Konkuk University, 05029 Seoul, Republic of Korea

Table 1. Selected serial clinicopathological and ultrasonographic findings before exploratory laparotomy.

Day	Key clinicopathological findings	Ultrasonographic findings	Clinical interpretation
Day 0	ALT >1000 U/L; AST 202 U/L; GGT 14 U/L; serum bilirubin 6.8 µmol/L (0.4 mg/dL); WBC 11.6 × 10^9/L; albumin 37 g/L (3.7 g/dL)	Gallbladder sludge-like echogenic material; no clinically meaningful effusion or obvious common bile duct dilation	Baseline evaluation; biliary leakage not confirmed
Day 2	ALT 513 U/L; AST 241 U/L; GGT 9 U/L	Vomiting improved, but gallbladder abnormality persisted	Clinical and biochemical improvement did not establish resolution
Day 4	ALT 291 U/L; AST 253 U/L; GGT 10 U/L; serum bilirubin 34.2 µmol/L (2.0 mg/dL)	New small-volume ascites and peritoneal change	Interval progression; effusion still insufficient for reliable sampling
Day 12	ALT 31 U/L; AST 44 U/L; GGT 9 U/L; serum bilirubin 22.2 µmol/L (1.3 mg/dL); fluid bilirubin 159.1 µmol/L (9.3 mg/dL)	Increased abdominal effusion and progressive peritonitis	Biliary leakage supported by abdominal fluid analysis
Day 13	Serum bilirubin 18.8 µmol/L (1.1 mg/dL); WBC 39.7 × 10^9/L; albumin 18 g/L (1.8 g/dL)	Further ascites progression	Continued progression before surgery

ALT, alanine aminotransferase; AST, aspartate aminotransferase; GGT, gamma-glutamyl transferase; WBC, white blood cell count.

remain limited and heterogeneous, including traumatic bile peritonitis, obstructive biliary disease, cholelithiasis, common bile duct perforation, biloma and cholecystectomy case series (Ludwig et al., 1997; Moores and Gregory, 2007; Simpson et al., 2022; Noguchi et al., 2023; Cosin Cifuentes et al., 2026). Although gallbladder rupture and bile peritonitis have previously been reported in cats, the clinical relevance of this case lies in the initially equivocal presentation, absence of marked hyperbilirubinemia and obvious common bile duct dilation, and progressive abnormalities documented by serial ultrasonography before definitive confirmation of biliary leakage. The aim of this report is to describe the clinical, imaging and surgical findings in a cat with gallbladder rupture and bile peritonitis with ambiguous initial clinicopathological and ultrasonographic findings.

Materials and methods

The medical record, serial clinicopathological and ultrasonographic findings, abdominal fluid analysis, culture and susceptibility testing, surgical and histopathological findings, and follow-up information were retrospectively reviewed. The client-owned cat received routine clinical care, and informed owner consent was obtained for diagnostic and therapeutic procedures and anonymised publication of clinical data and images. Ethical committee approval was not required for this retrospective case description.

Results

A 9-year-old spayed, female, domestic shorthair cat (*Felis catus*) was referred for vomiting, lethargy and anorexia. The cat was febrile (40.7°C) and mildly dehydrated. Initial serum biochemistry showed alanine aminotransferase activity greater than 1000 U/L, aspartate aminotransferase 202 U/L and gamma-glutamyl transferase 14 U/L, while serum total bilirubin was 6.8 µmol/L (0.4 mg/dL). Alkaline phosphatase activity was 80 U/L, white blood cell count was 11.6 × 10^9/L and albumin was 37 g/L (3.7 g/dL). Abdominal ultrasonography identified sludge-like echogenic material within the gallbladder lumen, but no obvious common bile duct dilation or clinically meaningful abdominal effusion was detected. Supportive management and scheduled reassessment were elected since biliary leakage was not confirmed upon presentation and no sufficient effusion was available for analysis. During the next two days, vomiting resolved and liver enzyme activities decreased, although the gallbladder abnormality persisted.

On day 4, repeat ultrasonography revealed new small-volume ascites, hyperechoic hepatic parenchyma and early peritoneal change. Serum total bilirubin increased to 34.2 µmol/L (2.0 mg/dL). These findings increased concern for progressive hepatobiliary disease; however, conservative management with close reassessment was continued due to insufficient effusion for reliable sampling, no confirmation of biliary leakage, and the cat showed partial clinical and biochemical improvement.

Figure 1. Day 0 abdominal ultrasonography. Sludge-like echogenic material was present within the gallbladder lumen (arrowhead). No clinically meaningful abdominal effusion was detected.

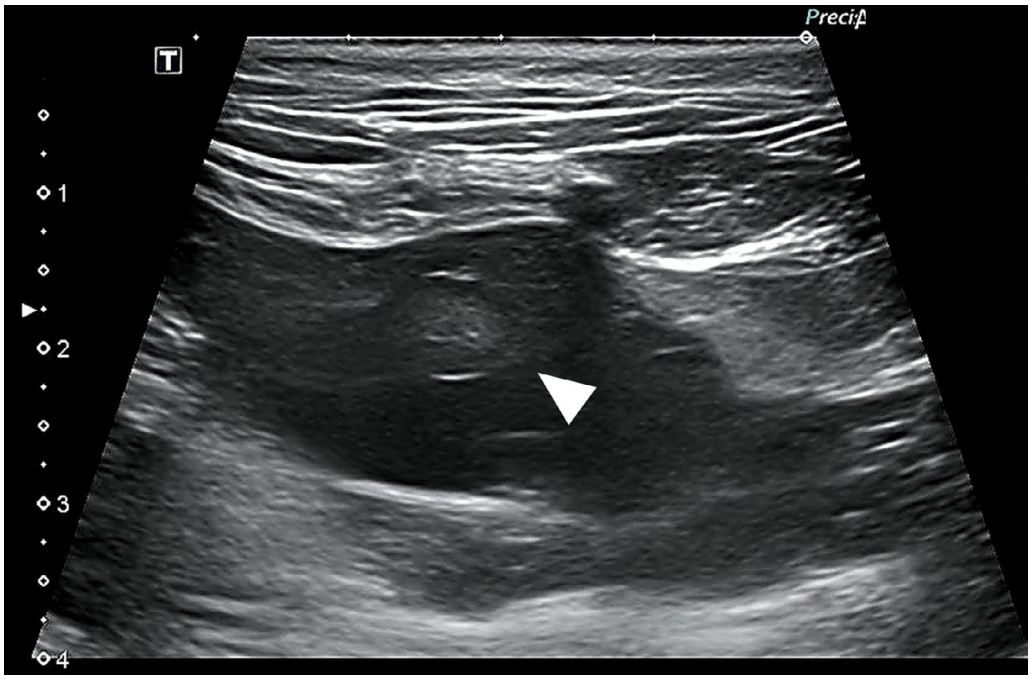

Figure 2. Day 4 abdominal ultrasonography. A small volume of newly developed anechoic abdominal effusion is indicated by the asterisk (*), with adjacent early peritoneal change.

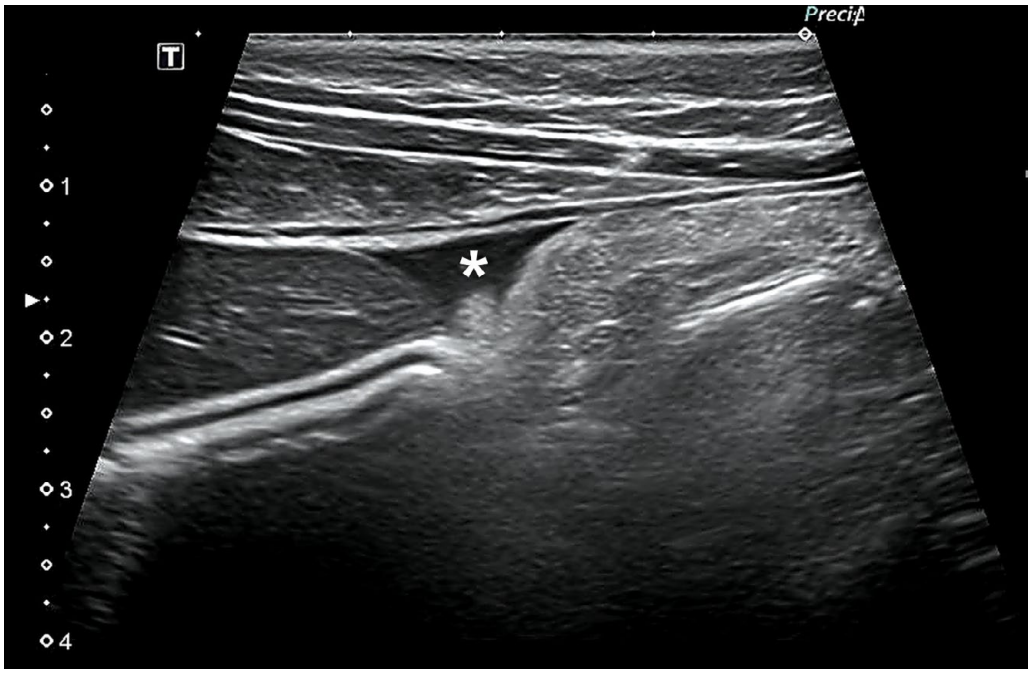

Immediate exploratory laparotomy was therefore deferred. The cat underwent interval re-evaluations during supportive management and was not continuously hospitalised between the initial presentation and day 12.

On day 12, the cat was re-evaluated because hyperthermia persisted (40.6°C) despite apparent systemic improvement. Liver enzyme activities had largely normalised, whereas serum total bilirubin was only mildly increased at 22.2 µmol/L (1.3 mg/dL). Repeat ultrasonography showed increased abdominal effusion around the liver and throughout the abdomen, with progressive peritonitis. Abdominocentesis yielded yellow, cloudy fluid. Cytology

Figure 3. Day 12 abdominal ultrasonography. Increased anechoic abdominal effusion is indicated by the double asterisks (**), accompanied by progressive peritoneal changes. These findings prompted abdominocentesis.

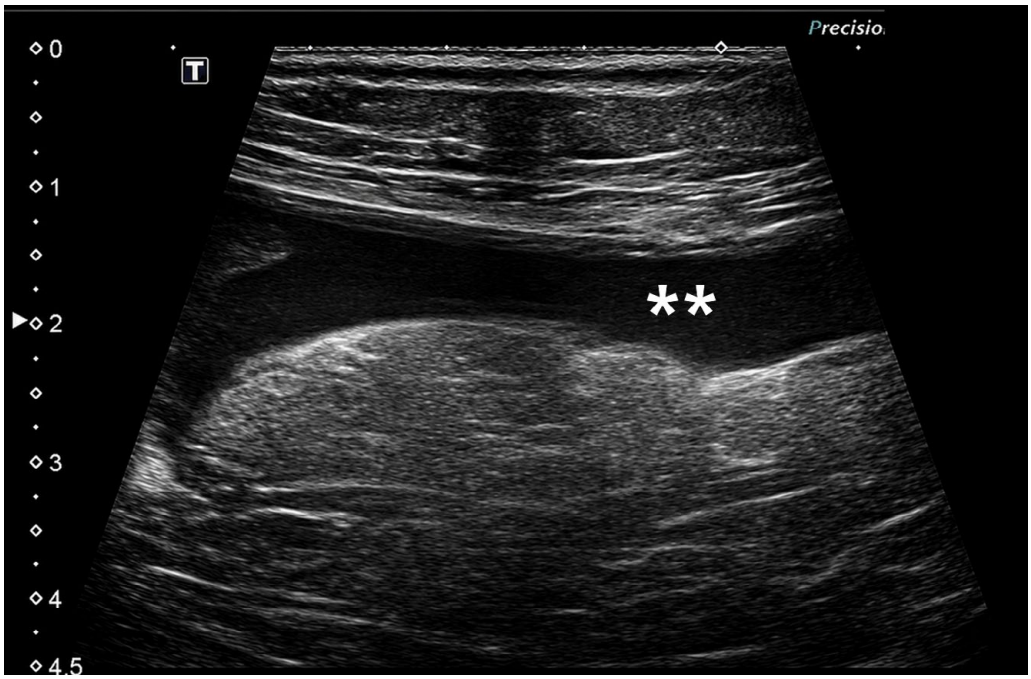



Figure 4. Abdominal fluid obtained by abdominocentesis on day 12. The fluid was yellow and cloudy. Abdominal fluid bilirubin concentration was 159.1 µmol/L (9.3 mg/dL), compared with a concurrent serum bilirubin concentration of 22.2 µmol/L (1.3 mg/dL).

showed marked neutrophilic inflammation with numerous degenerative neutrophils and occasional foamy macrophages, but no cytologically visible bacteria. The abdominal fluid bilirubin concentration was 159.1 µmol/L (9.3 mg/dL), exceeding the concurrent serum concentration of 22.2 µmol/L (1.3 mg/dL). Abdominal fluid was submitted for aerobic culture and antimicrobial susceptibility testing. Culture yielded Gram-negative bacterial growth, although species-level identification was not available. Disc diffusion susceptibility testing on Mueller-Hinton agar was performed, and the laboratory reported susceptibility to trimethoprim-sulfamethoxazole, amikacin and meropenem, with intermediate susceptibility to doxycycline and ciprofloxacin.

Feline coronavirus testing was negative. The combination of increasing abdominal effusion, progressive peritonitis, inflammatory abdominal fluid and marked fluid-to-serum bilirubin discordance provided sufficient evidence of biliary leakage to prompt urgent exploratory surgery.

On day 13, the cat underwent repeat evaluation during brief preoperative stabilisation. Icterus became more evident on physical examination. Preoperative reassessment showed further ascite progression, marked leukocytosis with neutrophilic predominance (white blood cell count 39.7 × 10^9/L;

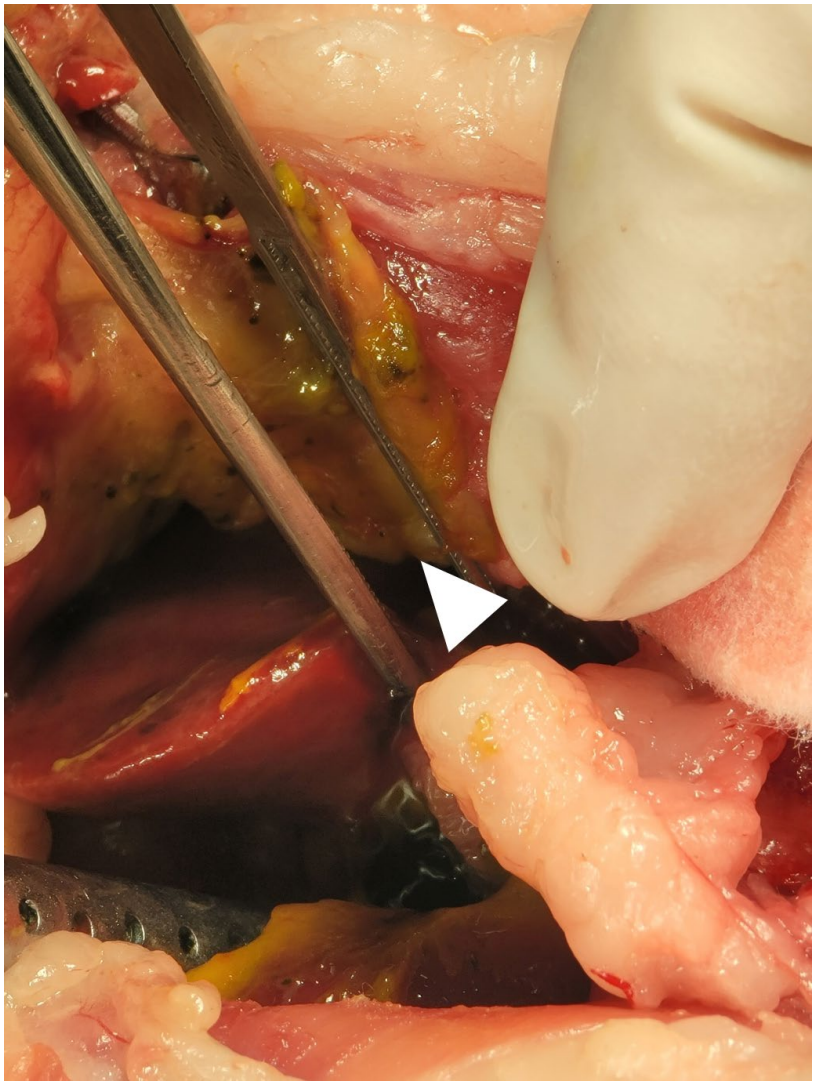

Figure 5. Intraoperative appearance of the ruptured gallbladder. The arrowhead indicates the ruptured gallbladder margin with adherent bile-stained material. Severe biliary contamination and extruded gallbladder contents were present in the surrounding abdomen.

granulocytes 37.6 × 10^9/L) and hypoalbuminemia (albumin 18 g/L [1.8 g/dL]), while serum bilirubin remained only mildly increased at 18.8 µmol/L (1.1 mg/dL). These findings indicated ongoing inflammatory deterioration despite the absence of marked hyperbilirubinemia, reinforcing the need for operative source control after brief preoperative stabilisation. Urgent exploratory laparotomy was then performed. At laparotomy, the omentum was adherent to the right abdominal wall and diffusely bile-stained. Blunt dissection released a large volume of bile-stained abdominal fluid. Extruded gallbladder contents adhered to the dorsal aspect of the right liver lobe, and severe biliary contamination was present throughout the abdomen. The gallbladder was extensively ruptured from the body to the neck, extending near the cystic duct-common bile duct junction. Intraoperative patency testing confirmed bile flow into the duodenum, and complete cholecystectomy was performed while preserving extrahepatic biliary patency. Copious peritoneal lavage, liver biopsy and closed abdominal drainage were performed.

Postoperative recovery was complicated by recurrent hypoalbuminemia, persistent anorexia and residual peritonitis. Initial postoperative management included trimethoprim-sulfamethoxazole, metronidazole and cefotaxime together with intravenous fluids, antiemetic, gastroprotective, analgesic and hepatobiliary supportive therapy. Human serum albumin (0.5 g/kg) was administered as rescue colloid support for marked hypoalbuminemia, increasing serum albumin from 16 to 33 g/L after the first administration and from 21 to 36 g/L after the second, without an acute adverse reaction. Because inflammatory abnormalities persisted during initial antimicrobial treatment and the Gram-negative isolate was reported as susceptible to meropenem, antimicrobial therapy was escalated to meropenem (10 mg/kg SC) from postoperative days 6 to 13 and discontinued following clinical and ultrasonographic improvement.

Abdominal inflammation gradually improved after source control. Histopathology of the gallbladder confirmed severe end-stage rupture

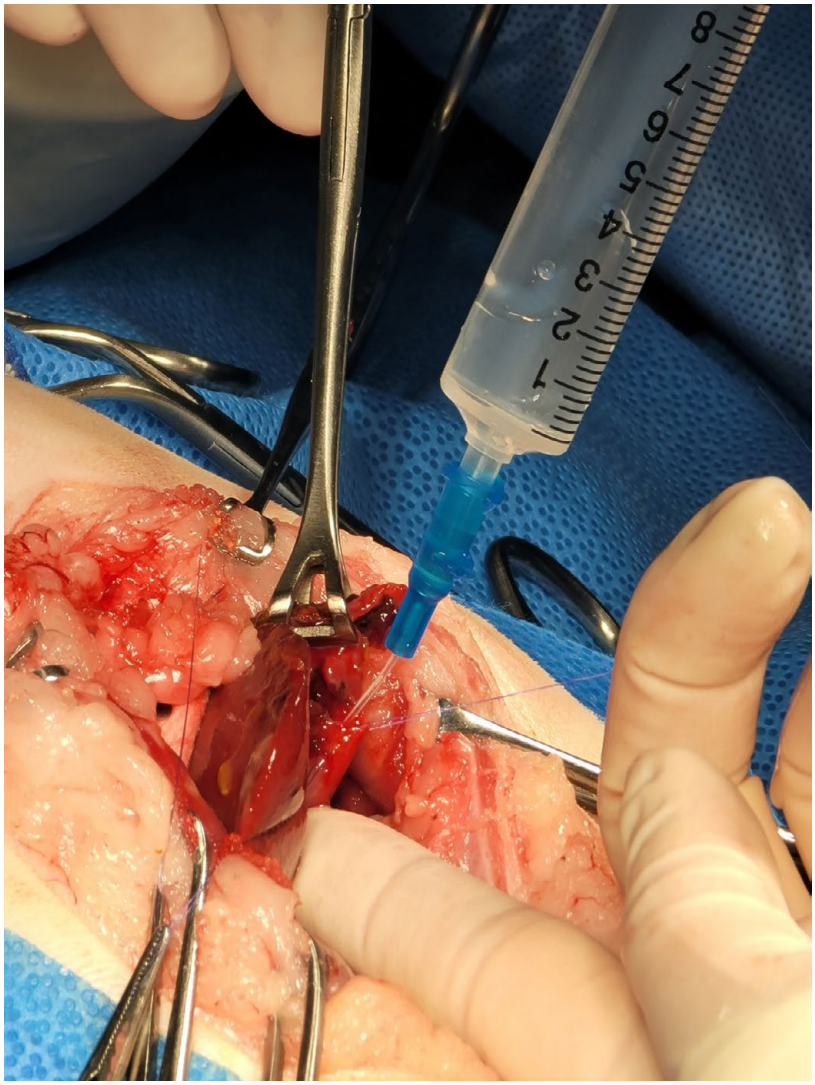

Figure 6. Intraoperative extrahepatic biliary patency testing before completion of cholecystectomy. Patency was confirmed by demonstrating flow into the duodenum.

with massive necrosis, granulation tissue and focal cystic mucosal hyperplasia. These findings were compatible with a possible underlying gallbladder mucocele, but severe rupture-associated destruction prevented definitive aetiological classification (Bennett et al., 2007). Liver biopsy showed acute neutrophilic hepatitis with mild glycogen-type vacuolar hepatopathy and diffuse cholestasis, interpreted as reactive to the gallbladder lesion. By postoperative day 20, peritonitis had markedly improved. At the final documented follow-up on postoperative day 538, the cat was alive and no major recurrent hepatobiliary problem had been reported.

Discussion

This case is clinically useful because it shows how a feline gallbladder rupture may remain difficult to confirm early when obstructive markers are not conspicuous. The initial examination did not reveal marked hyperbilirubinemia, obvious common bile duct dilation or sufficient effusion for fluid analysis. Nevertheless, serial ultrasonography later documented progression from a persistent gallbladder abnormality to ascites and peritonitis, and abdominal fluid analysis provided additional support once sampling became possible. This presentation is important for practitioners because the absence of marked serum bilirubin elevation or common bile duct dilation should not exclude clinically significant extrahepatic biliary disease. The interval between the initial detection of small-volume ascites on day 4 and surgical exploration illustrates the difficulty of determining the timing of intervention when biliary leakage cannot initially be confirmed and transient clinical improvement occurs despite progressive abdominal abnormalities.

In veterinary patients, abdominal fluid bilirubin measurement is an established adjunct for identifying biliary leakage (Ludwig et al., 1997; McAlexander et al., 2024). Ludwig et al. (1997) demonstrated its diagnostic value in dogs and cats with surgically confirmed bile peritonitis. In the present case, marked fluid-to-serum bilirubin dis-

cordance supported exploratory laparotomy when interpreted together with increasing abdominal effusion and progressive ultrasonographic peritonitis, rather than representing a novel diagnostic test.

Surgery served both diagnostic and therapeutic purposes. Laparotomy confirmed extensive bile contamination and rupture extending close to the cystic duct-common bile duct junction. Because bile flow into the duodenum was confirmed intraoperatively, cholecystectomy with preservation of extrahepatic biliary patency was appropriate. Bile-stained omental adhesions, adherent gallbladder contents and rupture-associated granulation tissue suggested that leakage may have been partially contained or ongoing before surgery, which may explain the mismatch between transient biochemical improvement and progressive abdominal disease.

Antimicrobial escalation was guided by the Gram-negative culture result, susceptibility testing and clinical reassessment in the setting of persistent postoperative biliary peritonitis. Although other susceptible antimicrobial options were identified, meropenem was selected after inflammatory abnormalities persisted during initial therapy. Given the critical importance of carbapenems, its use should be interpreted cautiously from an antimicrobial stewardship perspective, and it was discontinued following clinical and ultrasonographic improvement. The absence of species-level bacterial identification, lack of preoperative bile culture and inability to determine the primary cause of rupture were important limitations. Severe necrosis and inflammation limited histopathological interpretation; therefore, gallbladder mucocele was considered a possible underlying condition rather than a confirmed primary cause of rupture (Bennett et al., 2007).

Conclusions

Gallbladder rupture with bile peritonitis should remain a differential diagnosis in cats with persistent gallbladder abnormalities and progressive ascites or peritonitis, even when initial serum bilirubin concentration and common bile duct diameter are not strongly suggestive of obstruction. In this case, repeated ultrasonographic reassessment, abdominal fluid bilirubin analysis and exploratory laparotomy were integrated to diagnose and treat extensive gallbladder rupture. The report adds an educational clinical and surgical example rather than a novel diagnostic rule.

Acknowledgements

The authors thank 24Soom Animal Hospital, Greenvet and the clinicians involved in this case for assistance with case documentation and diagnostic evaluation. The authors received no financial support and declare no conflicts of interest.

> References

- BRAIN, P. H., V. R. BARRS, P. MARTIN, R. BARAL, J. D. WHITE and J. A. BEATTY. (2006): Feline cholecystitis and acute neutrophilic cholangitis: clinical findings, bacterial isolates and response to treatment in six cases. J. Feline Med. Surg. 8, 91-103. 10.1016/j.jfms.2005.09.001.
- BENNETT, S. L., M. MILNE, R. F. SLOCOMBE, A. E. MORTON and J. M. CHURCHER. (2007): Gallbladder mucocoele and concurrent hepatic lipidosis in a cat. Aust. Vet. J. 85, 397-400. 10.1111/j.1751-0813.2007.00192.x.
- COSIN CIFUENTES, S., C. SANCHEZ JIMENEZ, M. J. DOBROMYLSKYJ and S. W. J. GREGORY. (2026): Biloma in a cat with cholelithiasis and suspected previous biliary peritonitis due to gallbladder rupture. J. Feline Med. Surg. Open Rep. 12, 20551169261422315. 10.1177/20551169261422315.
- GRIFFIN, S. (2019): Feline abdominal ultrasonography: what is normal? What is abnormal? The biliary tree. J. Feline Med. Surg. 21, 429-441. 10.1177/1098612X19843212.
- MOORES, A. L. and S. P. GREGORY. (2007): Duplex gall bladder associated with choledocholithiasis, cholecystitis, gall bladder rupture and septic peritonitis in a cat. J. Small Anim. Pract. 48, 404-409. 10.1111/j.1748-5827.2006.00268.x.
- LOW, D. and J. WILLIAMS. (2023): Surgical management of feline biliary tract disease: decision-making and techniques. J. Feline Med. Surg. 25, 1098612X231206846. 10.1177/1098612X231206846.
- MCALEXANDER, H. W., J. A. GRIMES, S. L. ULLMAN, G. P.-C. LAI, M. DAVIS, B. G. DARROW and V. M. DICKERSON. (2024): Diagnostic and surgical treatment for traumatic bile peritonitis in dogs and cats. J. Am. Vet. Med. Assoc. 262, 1-6. 10.2460/javma.24.01.0049.
- LUDWIG, L. L., M. A. MCLOUGHLIN, T. K. GRAVES, J. CRISP and M. J. RIGGS. (1997): Surgical treatment of bile peritonitis in 24 dogs and 2 cats: a retrospective study (1987-1994). Vet. Surg. 26, 90-98.
- NOGUCHI, A., T. IWANAGA, N. MIURA, T. SOGAWA, M. FUJIKI. (2023): Common bile duct perforation due to choledocholithiasis in a cat with gallbladder agenesis. J. Feline Med. Surg. Open Rep. 9, 20551169221146513. 10.1177/20551169221146513.
- OTTE, C. M. A., L. C. PENNING and J. ROTHUIZEN. (2017): Feline biliary tree and gallbladder disease: aetiology, diagnosis and treatment. J. Feline Med. Surg. 19, 514-528. 10.1177/1098612X17706465.
- SIMPSON, M., J. NEVILLE-TOWLE, K. C. LEE, M. ROSSANESE. (2022): Cholecystectomy in 23 cats (2005-2021). Vet. Surg. 51, 109-116. 10.1111/vsu.13746.

> Ruptura žučnog mjehura s bilijarnim peritonitisom u mačke: Klinički, ultrazvučni i kirurški nalazi

Yongwon PARK[1], spid19@naver.com, orcid.org/0009-0007-8194-1206; A-Jin LEE[2], orelieaj@gmail.com; Do-Hyun SEO[2], dodoseo1270@daum.net; Hwi-Yool KIM[3]* (dopisni autor), hykim@konkuk.ac.kr, orcid.org/0000-0001-6237-9958.
[1]24Soom Animal Hospital, 16568 Suwon, Republic of Korea; Department of Veterinary Surgery, College of Veterinary Medicine, Konkuk University, 05029 Seoul, Republic of Korea
[2]24Soom Animal Hospital, 16568 Suwon, Republic of Korea;
[3]Department of Veterinary Surgery, College of Veterinary Medicine, Konkuk University, 05029 Seoul, Republic of Korea

Ruptura žučnog mjehura s posljedičnim peritonitisom nije česta kod mačaka i teško ju je dijagnosticirati ako nisu prisutni karakteristični klinički znakovi opstrukcije. Devetogodišnja sterilizirana ženka domaće kratkodlake mačke dovedena je zbog povraćanja, letargije, anoreksije i vrućice. Početni pregled otkrio je značajno povišenje hepatocelularnih enzima bez hiperbilirubinemije, bez očite dilatacija glavnog žučovoda i bez klinički značajnog abdominalnog izljeva. Serijskim ultrazvučnim pregledima utvrđen je progresivni ascites i peritonitis, unatoč prolaznom kliničkom i biokemijskom poboljšanju. Dvanaestog dana koncentracija bilirubin u abdominalnoj tekućini bila je 159,1 µmol/L (9,3 mg/dL), u usporedbi s istodobnim koncentracijom serumskog bilirubina od 22,2 µmol/L (1,3 mg/dL). Eksplorativna laparotomija učinjena je 13. dana i potvrdila je opsežnu rupturu žučnog mjehura i teški peritonitis. Kolecistektomija je izvedena nakon potvrde prohodnosti ekstrahepatičkih žučnih putova, nakon čega je uslijedilo ispiranje i drenaža. Mačka je preživjela do 538. postoperativnog dana. Ovaj slučaj ukazuje na značaj dijagnostike serijskim ultrazvučnim pregledima, analize abdominalne tekućine i operativnog zahvata kod nespecifičnih početnih simptoma rupture žučnog mjehura u mačaka.

Ključne riječi: *abdominalni izljev; bilijarni peritonitis; kolecistektomija; ekstrahepatična bilijarna bolest; ruptura žućnog mjehura; ultrazvuk*.