| CASE REPORT |

Epidural Autologous Platelet-Rich Plasma in a French Bulldog with Chronic Spinal Cord Dysfunction Associated with Vertebral Malformations: A Case Report

B. Pehar
H. Milošević
M. Obhođaš
A. Maksimović*

https://doi.org/10.46419/cvj.58.1.5

Received: 14 April 2026
Accepted: 22 September 2026
Online publication: 30 November 2026

Abstract

Platelet-rich plasma (PRP), an autologous blood product enriched with growth factors, supports tissue regeneration, reduces inflammation, and promotes neural repair. Though widely used in orthopaedics, its epidural use for spinal cord dysfunction in dogs remains unexplored. This case report describes an 8-year-old spayed female French Bulldog with progressive paraparesis, proprioceptive deficits, and urinary/faecal incontinence. MRI and CT revealed vertebral malformations, a probable arachnoid diverticulum, and spinal cord compression. Corticosteroid therapy improved temporarily but relapsed upon tapering. Epidural PRP was administered on days 0, 15, 30, and 45 using a two-step centrifugation protocol. The procedure was well tolerated without sedation or anaesthesia. Neurological improvement was observed, with restoration of ambulation and reduced proprioceptive deficits, as assessed by the Texas Spinal Cord Injury Scale. This suggests PRP may be a safe, minimally invasive, and promising adjunctive treatment for spinal cord dysfunction in dogs.

Key words: ***Platelet-rich plasma; epidural therapy; spinal cord dysfunction; dog (canine); neurological recovery.***

Introduction

Platelet-rich plasma (PRP) is an autologous biological product containing concentrated platelets and a range of bioactive mediators involved in haemostasis, angiogenesis, extracellular matrix remodelling, and tissue repair. Among the principal growth factors released from activated platelets are platelet-derived growth factor (PDGF), transforming growth factor-beta (TGF-β), vascular endothelial growth factor (VEGF), insulin-like growth factor (IGF), and epidermal growth factor (EGF). Through the local release of these mediators, PRP may pro-

CC BY

Bianca PEHAR, drbiancapehar@gmail.com, orcid.org/0009-0007-7160-0934; Hrvoje MILOŠEVIĆ, hrvoje.milosevic@vfs.unsa.ba, orcid.org/0000-0003-4625-5888; Muamer OBHOĐAŠ, muamer.obhodjas@vfs.unsa.ba, orcid.org/0000-0001-7489-4279; Alan MAKSIMOVIĆ* (corresponding author), alan.maksimovic@vfs.unsa.ba, orcid.org/0000-0002-4127-9445.

Department of Clinical Sciences, Faculty of Veterinary Medicine University of Sarajevo, 71000 Sarajevo, Bosnia and Herzegovina.

mote neovascularisation and improve microcirculatory conditions within damaged tissues, potentially supporting oxygen delivery and metabolic exchange in chronically compromised environments (Everts et al., 2020; Wu et al., 2025). Although these growth factors are not typical neurotrophic factors (NTFs), they may exert neuroprotective and tissue-supportive effects within the nervous system (Shen et al., 2009). Several studies suggest that PRP possesses substantial clinical value and potential for nerve repair and pain modulation (Wang et al., 2024). The evidence supporting neurological applications of PRP, however, originates from heterogeneous experimental and clinical settings and should be interpreted according to the underlying disease model. In peripheral nerve injury models, PRP has been associated with enhanced Schwann cell proliferation, axonal regeneration, and functional recovery. For example, Zheng et al. (2013) reported increased Schwann cell proliferation and secretory activity in an experimental sciatic nerve model. More recent studies have further explored the potential role of PRP in peripheral nerve repair and pain modulation (Armitage et al., 2023; Wang et al., 2024). These findings provide biological plausibility for neural applications of PRP but cannot be directly extrapolated to spinal cord disease, where the cellular environment, pathophysiology, and regenerative capacity differ substantially from those of peripheral nerves.

Neurological deficits are a prevalent concern in dogs, commonly resulting from conditions such as degenerative lumbosacral stenosis (DLS), intervertebral disc disease (IVDD), and spinal cord injuries (Hernández-Guerra et al., 2021). Traditional treatments include surgical decompression, corticosteroid administration, and rehabilitation; however, these methods are not always effective, and long-term management can be challenging (Worth et al., 2019). Clinical evidence for epidural PRP in canine spinal disorders remains limited and condition-specific. The most relevant published canine data include its use in degenerative lumbosacral disease. Hernández-Guerra et al. (2021) reported improvements in mobility and pain-related outcomes in retired working dogs following epidural PRP administration. Such observations suggest that epidural PRP may have potential as an adjunctive treatment in selected spinal disorders; however, they do not establish efficacy for other neurological conditions or demonstrate a specific mechanism of action. When administered epidurally, PRP provides a targeted approach that reduces inflammation, accelerates nerve regeneration, and enhances functional recovery (Hernández-Guerra et al., 2021; Mayoral Rojals et al., 2023). Comparative studies suggest that PRP may even outperform corticosteroids in managing chronic spinal pain and neurological deficits, without the associated side effects (Wang et al., 2024; Zhang et al., 2025). Evidence concerning the use of PRP in canine thoracolumbar spinal cord disease is considerably more limited. In particular, direct clinical studies evaluating epidural PRP for neurological dysfunction associated with congenital vertebral malformations, spinal arachnoid diverticula, or chronic thoracolumbar spinal cord compression appear to be lacking. Consequently, extrapolation from peripheral nerve models, experimental spinal cord injury, human studies, or canine degenerative lumbosacral disease should be made cautiously.

The present case describes the clinical course following epidural administration of autologous PRP in a dog with chronic neurological dysfunction associated with multiple vertebral malformations, a probable spinal arachnoid diverticulum, and chronic spinal cord compression. The case is intended to provide preliminary clinical information rather than evidence of efficacy or a defined mechanism of action. Further controlled studies are required to determine whether PRP has therapeutic value in comparable canine spinal disorders and to establish appropriate patient selection, PRP preparation protocols, administration techniques, dosing schedules, safety, and long-term outcomes.

Material and Methods

An 8-year-old spayed female French Bulldog, weighing 12 kg, was referred due to worsening hind limb mobility over three months, with marked decline in the past three weeks. No pain was observed. Urinary incontinence had been present for over two years and was reported to have become more pronounced and intermittently frequent in association with the decline in hind limb mobility. Clinical signs included episodes of stranguria and polyuria. The medical history included chronic atopic dermatitis, recurrent urinary tract infections (UTI), cystitis, struvite urolithiasis, and chronic bilateral otitis externa. Identified causes of UTIs were isolates of *Proteus mirabilis*, *Escherichia coli*, and *Enterococcus* spp. Each episode was successfully treated with a three-week course of targeted antibiotics (e.g., trimethoprim–sulfamethoxazole or marbofloxacin) guided by antimicrobial susceptibility testing. A urinary prescription diet (Royal Canin Urinary S/O) and adjunctive supplements (D-mannose and probiotics) were implemented to reduce recurrence risk. At the time of referral, the dog was receiving marbofloxacin for UTI, oclacitinib for chronic atopic dermatitis, and was also on nutraceutical support (spirulina, L-carnitine, and methylcobalamin). A comprehensive neurological examination was performed, including assessment of gait, proprioception, spinal reflexes, muscle tone, perineal reflex, deep pain perception,

Table 1. Selected serial clinicopathological and ultrasonographic findings before exploratory laparotomy.

Gait[a]	
0	no voluntary movement seen when supported
1	intact limb protraction with no ground clearance
2	intact limb protraction with inconsistent ground clearance
3	intact limb protraction with consistent ground clearance (>75%)
4	ambulatory, consistent ground clearance with moderate paresis–ataxia (will fall occasionally)
5	ambulatory, consistent ground clearance with mild paresis–ataxia (does not fall, even on slick surfaces)
6	normal gait
Proprioceptive positioning[b]	
0	absent response
1	delayed response
2	normal response
Nociception[c]	
0	no deep nociception
1	intact deep nociception, no superficial nociception
2	nociception present

[a] Ground clearance refers to the ability to lift the limb off of the ground when it is being protracted.

[b] Proprioceptive positioning is performed by supporting the dog's weight and gently placing the dorsum of the paw on the ground. A delayed response is indicated by a greater than 2 s lag between paw placement and correction.

[c] Deep nociception is measured by cross-clamping the distal limb or nail bed with hemostats. Superficial nociception is tested by pinching the inter-digital webbing with hemostats.

and cranial nerve function. Diagnostic work-up included haematology and biochemistry analyses (complete blood count, C-reactive protein, and coagulation profile). Advanced imaging consisted of magnetic resonance imaging (MRI) and computed tomography (CT) to evaluate structural abnormalities of the vertebral column and spinal cord.

Blood for PRP preparation was collected aseptically from the cephalic vein. Approximately 10 mL peripheral venous blood was collected aseptically into citrate-containing tubes from the PRGF-Endoret® system (BTI Biotechnology Institute, Vitoria, Spain), as previously described for epidural PRP preparation in dogs by Hernández-Guerra et al. (2021). However, rather than using the standard single-centrifugation PRGF-Endoret® protocol, the collected blood was processed using a modified two-step centrifugation procedure adapted from Alves et al. (2021). The first centrifugation was performed at 3600 rpm for 1 min, after which the plasma-containing supernatant was transferred aseptically to a sterile tube. A second centrifugation at 3800 rpm for 5 min was then performed to further concentrate the platelet-containing fraction. Excess platelet-poor plasma was removed, leaving approximately 2–4 mL concentrated autologous plasma, which was gently resuspended and administered epidurally without exogenous platelet activation. A single dose of autologous PRP was administered epidurally in the lumbosacral region on days 0, 15, 30, and 45. Prior to epidural administration, the lumbosacral region was aseptically prepared. A topical prilocaine cream was then applied to minimise cutaneous nociceptive response. The patient was positioned in sternal recumbency with the pelvic limbs flexed cranially to facilitate optimal access to the lumbosacral intervertebral space. A 22-gauge spinal needle was introduced on the midline at the L7–S1 junction and advanced perpendicular to the skin. Correct needle placement within the epidural space was verified using both the hanging drop and loss-of-resistance techniques. Approximately 2–4 mL autologous platelet-rich plasma (PRP) was administered slowly over 30–60 seconds. The patient was maintained in sternal recumbency for an additional 20 minutes following injection to promote appropriate distribution of the injectate. The procedure was well tolerated, and no immediate adverse effects or procedural complications were observed. PRP was administered epidurally as a biological adjunct targeting chronic inflammatory

Figure 1. Magnetic resonance imaging of the thoracolumbar spine. MRI demonstrating multiple vertebral anomalies, including a supernumerary T14 vertebra and hemivertebrae (T6–T9, T11), with a probable dorsolateral arachnoid diverticulum at T10–T11 (left-sided predominance) causing moderate to severe spinal cord compression. Additional findings include intervertebral disc degeneration, lumbosacral spondylosis, and multilevel disc protrusions.

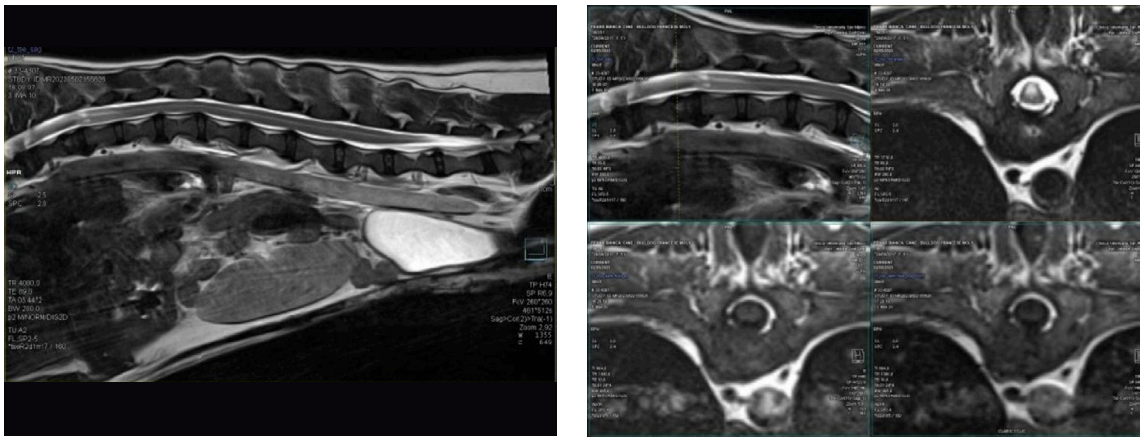

and secondary degenerative changes within the compressed thoracolumbar spinal cord segment. The treatment was not intended to correct congenital vertebral malformations, but rather to modulate the inflammatory microenvironment associated with long-standing spinal cord compression and potentially support endogenous repair mechanisms.

Post-treatment neurological status was evaluated using the Texas Spinal Cord Injury Score (TSCIS) for Dogs (Table 1), as detailed by Levine et al. (2009), to track functional recovery. The TSCIS assesses each pelvic limb independently across three domains: gait (scored 0–6), postural reactions (0–2), and nociception (0–2), with a maximum of 10 points per limb and a total possible score of 20 for both pelvic limbs. Gait was assessed during ambulation on a flat, non-slip surface, evaluating limb movement, coordination, and weight-bearing ability. Postural reactions were tested using the paw placement method, while nociception was evaluated by applying a standardised noxious stimulus to the digits and observing for a conscious response. Structured rehabilitation protocols, encompassing passive range-of-motion exercises, assisted standing, and controlled gait training, were implemented.

Figure 2. Computed tomography evaluation of vertebral malformations and multilevel intervertebral disc protrusions Computed tomography confirming vertebral malformations and multilevel disc protrusions identified on the MRI, with additional cervical disc protrusions at C2–C3 (mild), C4–C5 (moderate), and C5–C6 (mild).

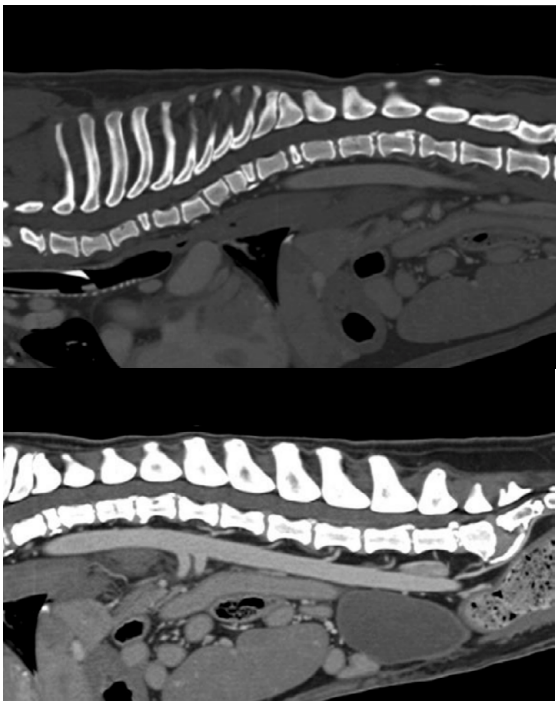

Results

Neurological examination revealed bilateral paraparesis, with the patient being non-ambulatory at presentation. Proprioceptive positioning was absent in both pelvic limbs. Segmental spinal reflexes of the pelvic limbs exhibited hyperreflexia, with a more pronounced effect on the right pelvic limb, encompassing the patellar, cranial tibial, and gastrocnemius reflexes. The flexor reflex was present bilaterally, although mildly reduced on the left pelvic limb. Muscle tone was mildly decreased in the left pelvic limb and within normal limits in the right pelvic limb. Perineal reflex, anal tone, and tail tone were preserved. Deep pain perception was present in both pelvic limbs. The cutaneous trunci reflex was intact with a caudal border at approximately the T12–T13 level. Cranial nerve examination was unremarkable, and no

Table 2. Longitudinal Texas Spinal Cord Injury Score (TSCIS) during clinical follow-up. Higher scores indicate better neurological function. TSCIS was assessed according to Levine et al. (2009).

Follow-up	Gait (0–6)	Proprioceptive positioning (0–2)	Nociception (0–2)	Total TSCIS (0–10)	Clinical interpretation
Baseline	1	0	1	2	Non-ambulatory paraparesis
Day 3	3	1	1	5	Early motor improvement
Day 10	4	1	2	7	Ambulatory; improved pelvic-limb function
Day 14	3	1	2	6	Mild residual neurological deficits

spinal pain was elicited on palpation of the vertebral column. The mild hypotonia and reduced reflexes in the left pelvic limb were considered consistent with asymmetric dorsolateral spinal cord compression, which may result in superimposed segmental lower motor neuron-like signs in chronic cases. Blood test revealed slight leukopenia and thrombocytopenia, CRP slightly elevated, and slightly prolonged aPTT, while other parameters were within normal physiological ranges. The MRI (Figure 1) detected multiple vertebral anomalies, including a supernumerary thoracic vertebra (T14) and butterfly/hemivertebrae at T11 and within the T6–T9 region, without relevant deviation or stenosis of the vertebral canal.

A probable dorsolateral arachnoid diverticulum at T10–T11, more pronounced on the left side, was identified, resulting in moderate to severe spinal cord compression and associated damage. Moderate to severe intervertebral disc degeneration was noted, with more pronounced vertebral spondylosis at the lumbosacral level and disc protrusions at multiple sites. CT imaging (Figure 2) confirmed the vertebral malformations and disc protrusions previously identified on the MRI. Additionally, cervical disc protrusions were observed, with varying degrees of compression in C2–C3 (mild compression), C4–C5 (moderate compression), and C5–C6 (mild compression).

Additional systemic findings included diffuse splenopathy, chronic inflammatory enteropathy, bilateral degenerative inflammatory knee arthropathy, thymic hyperplasia, and bilateral middle and external otopathy.

After each administration, the patient was rested for three consecutive days and examined by a veterinarian on days 1 and 3 post-procedure to identify signs of exacerbated pain, persistent stiffness of gait, or posture changes. If no complaints were registered, the animal was allowed to resume its normal activity (Alves et al., 2021). Neurological assessments using TSCIS scoring system were conducted at baseline and subsequently repeated at regular intervals, specifically on days 3, 10, and 14 post-PRP treatment, to monitor progression. All evaluations were performed by the same clinician to ensure consistency. Following PRP administration, the dog demonstrated notable neurological improvement. The TSCIS score increased from a baseline of 2 points per limb to 5 on day 3, 7 on day 10, and 6 on day 14 (Table 2). The dog gradually regained ambulatory ability, with marked improvement in hind limb proprioception and strength. Gait quality was noticeably improved on grass and carpeted surfaces, while it remained compromised on smooth surfaces such as tile or parquet. By the final follow-up on day 59, urinary continence had been restored, and only mild proprioceptive deficits persisted in the pelvic limbs. No adverse effects were observed during the treatment period. The dog's chronic dermatological condition stabilised following the discontinuation of marbofloxacin and remained well-controlled under Lokivetmab therapy.

Discussion

In recent years, regenerative approaches for spinal and neurological disorders in veterinary medicine have increasingly focused on two principal biological modalities: platelet-rich plasma (PRP) and mesenchymal stem cells (MSC). While both therapies share regenerative and anti-inflammatory properties, they differ substantially in their biological mechanisms, clinical practicality, regulatory complexity, and safety profile. PRP was selected in the present case primarily due to its established safety, ease of preparation, cost-effectiveness, and minimal regulatory burden. PRP is increasingly recognised for its regenerative properties in both human and veterinary medicine. It contains a concentrated pool of autologous growth factors that stimulate angiogenesis, modulate inflammation, and promote axonal regeneration (Wu et al., 2025). These characteristics make PRP particularly suitable for epidural application, where rapid biological modulation rather than cellular engraftment is desired. MSCs act primarily through paracrine signalling and immunomodulatory pathways, with proposed benefits in neural regeneration and axonal repair (Picazo et al., 2024). However, their use is associated with greater

logistical complexity, higher financial costs, the need for cell culturing, longer preparation times, and stricter regulatory oversight. Furthermore, the evidence supporting epidural or intrathecal stem cell administration in dogs remains limited to experimental or highly selected clinical cases, with inconsistent outcomes (Bach et al., 2019; Vikartovska et al., 2020). Therefore, PRP was chosen over stem cell therapy in the present case as a pragmatic, biologically sound, and clinically promising approach, offering regenerative potential with a more predictable safety profile and simpler implementation. Although well established in musculoskeletal and orthopaedic applications, the use of PRP for treating spinal cord injuries and compressive myelopathies in veterinary neurology remains under-investigated. In this case, epidural PRP administration was initiated after conventional corticosteroid therapy yielded only transient improvement. The dog presented with clinical signs suggestive of a compressive myelopathy, supported by imaging findings of vertebral anomalies and probable arachnoid diverticulum. Experimental models have demonstrated the capacity of PRP to promote myelin regeneration, inhibit muscle atrophy, and facilitate axonal repair. Salarinia et al. (2017) documented marked functional recovery in rats with spinal cord injury by week five following PRP treatment. Castro et al. (2019) showed that PRP restored sensorimotor reflexes and allowed for afferent nerve re-entry into the spinal cord without provoking glial scarring or adverse reactivity. Veterinary clinical data, though limited, support these findings. Hernández-Guerra et al. (2021) reported substantial improvement in mobility and pain scores in retired working dogs with degenerative lumbosacral stenosis treated with epidural PRP. In a recent study by Bussières et al. (2024), epidural PRP improved locomotion and pain control over five months in dogs with lumbosacral disease, with fewer complications than repeat corticosteroid injections. Positive effects of PRP on bone and tendon healing and early function were also observed (Vidal-Negreira et al., 2025). In the present case, PRP was administered epidurally on four occasions without the need for sedation or anaesthesia. Four epidural administrations of autologous PRP were performed at 15-day intervals, on Days 0, 15, 30, and 45. As no standardised epidural PRP protocol has been established for canine chronic compressive spinal cord disease, the treatment schedule represented a pragmatic clinical adaptation of previously reported serial PRP protocols. Hernández-Guerra et al. (2021) administered epidural PRP on days 0, 15, and 45 in dogs with degenerative lumbosacral stenosis, while repeated PRP administration at approximately two-week intervals has also been described in other canine applications (Alvest et al., 2021). In the present case, an additional administration on day 30 was incorporated to maintain a uniform 15-day interval over the six-week treatment period. This schedule should therefore be regarded as empirical rather than as an established or optimised treatment regimen. Neurological improvement was observed following PRP administration, including improved proprioception, and recovery of nociception in the pelvic limbs. This aligns with prior evidence suggesting PRP may provide sustained neurological improvement by attenuating inflammatory cascades and promoting endogenous repair mechanisms. Importantly, PRP has a favourable safety profile. Most reported adverse effects are mild, such as transient local discomfort or inflammation due to platelet activation. In our case, coagulation screening prior to administration revealed mild thrombocytopenia and slightly prolonged aPTT, without overt signs of bleeding or coagulopathy. Given the known breed predisposition in French Bulldogs to congenital platelet function disorders, careful monitoring and platelet concentration adjustments were made during PRP preparation. No thrombotic or haemorrhagic events occurred during or after treatment. A limitation of this study is the absence of direct cellular characterisation of the PRP administered in this patient. Platelet, leukocyte, and erythrocyte concentrations were not determined in the final preparation; consequently, platelet enrichment and the cellular classification of the PRP cannot be established retrospectively. Growth-factor concentrations were also not measured. Although the preparation procedure and activation status are reported to facilitate reproducibility, variability in PRP composition cannot be excluded. Therefore, the biological composition of the administered product should not be inferred solely from previously published data obtained using similar preparation protocols. Although secondary neuroinflammatory processes may occur in association with chronic spinal cord compression, their presence was not specifically confirmed in this patient. Corticosteroids may be used to modulate inflammation and oedema associated with spinal cord injury; however, their effects are nonspecific and a clinical response cannot be considered evidence of an inflammatory aetiology. In this case, epidural PRP administration initiated after conventional corticosteroid therapy yielded only transient clinical improvement. PRP presents a promising biological alternative or adjunct, particularly in recurrent or steroid-resistant cases. Unlike corticosteroids, PRP has not been associated with progressive fibrosis or suppression of intrinsic repair pathways. The use of objective scoring systems is essential to reliably assess neurological recovery. While the Modified Frankel Scale (MFS) has been widely used, it offers limited resolution and inter-rater agreement. The TSCIS, developed by Levine et al. (2009), allows independent scoring of pelvic limb function, including gait, proprioception, and nociception, offering greater sensitivity in detecting neurological improvement. In this case, the

TSCIS proved useful in tracking the dog's clinical progress and response to treatment. Considering the chronic nature of spinal cord compression and the severity of neurological deficits, rehabilitation was incorporated as an adjunctive component of management. Structured rehabilitation protocols, encompassing passive range-of-motion exercises, assisted standing, and controlled gait training, have demonstrated efficacy in supporting functional recovery and mitigating secondary musculoskeletal complications in canine patients with spinal cord injury (Millis and Levine, 2014). Basic supportive rehabilitation included in the management of this patient should be considered a potential contributor to functional recovery. However, the rehabilitation programme was limited, and did not include intensive or equipment-based modalities such as underwater treadmill therapy, electrical stimulation, photobiomodulation, or advanced proprioceptive and balance training. Randomised studies in dogs with thoracolumbar intervertebral disc disease have not demonstrated a clear improvement in the rate or extent of neurological recovery attributable to basic rehabilitation compared with standard care, nor has more intensive rehabilitation consistently outperformed basic programmes. Bennaim et al. (2017), for example, found no marked difference in time to functional recovery or ambulation between dogs receiving basic postoperative physical rehabilitation and those receiving standard postoperative care without rehabilitation. Similarly, Zidan et al. (2018) found that an intensive, staged rehabilitation programme did not improve the rate or level of recovery compared with a basic programme consisting primarily of passive range-of-motion exercises and assisted walking. Nevertheless, these studies involve disease processes different from the chronic structural and compressive spinal cord dysfunction present in this patient. Therefore, a contribution of basic rehabilitation to the observed recovery cannot be excluded, but its magnitude cannot be determined from the present case. Another limitation is the absence of a follow-up MRI. Although neurological improvement was documented clinically, post-treatment MRI was not performed; therefore, it was not possible to assess whether the clinical changes were accompanied by alterations in spinal cord compression, intramedullary signal abnormalities, or the probable arachnoid diverticulum. Consequently, the observed recovery should be interpreted as a functional clinical outcome and not as evidence of structural improvement or resolution of the underlying spinal lesions. This report describes a single clinical case, which inherently limits the generalisability of the findings and precludes definitive conclusions regarding treatment efficacy. The absence of a control group and limited long-term follow-up further restrict interpretation. Controlled clinical studies are required to evaluate the role of epidural PRP as an adjunctive therapy in chronic compressive myelopathies.

In summary, this case supports the potential utility of epidural PRP as a safe, minimally invasive adjunctive treatment for spinal cord dysfunction in dogs. The observed neurological improvements, combined with a lack of adverse effects, are consistent with findings from both preclinical and limited clinical studies. Further controlled trials are warranted to optimise dosing protocols, define candidate selection criteria, and evaluate long-term outcomes in veterinary neurology.

> References

- ALVES, J. C., A. SANTOS and P. JORGE (2021): Platelet-rich plasma therapy in dogs with bilateral hip osteoarthritis. BMC Vet. Res. 17, 207. 10.1186/s12917-021-02913-x.
- ARMITAGE, A. J., J. M. MILLER, T. H. SPARKS, A. E. GEORGIOU and J. REID (2023): Efficacy of autologous mesenchymal stromal cell treatment for chronic degenerative musculoskeletal conditions in dogs: A retrospective study. Front. Vet. Sci. 9, 1014687. 10.3389/fvets.2022.1014687.
- BACH, F. S., C. K. L. REBELATTO, L. FRACARO, A. C. SENEGAGLIA, F. Y. I. FRAGOSO, D. R. DAGA et al. (2019): Comparison of the efficacy of surgical decompression alone and combined with canine adipose tissue-derived stem cell transplantation in dogs with acute thoracolumbar disk disease and spinal cord injury. Front. Vet. Sci. 6, 383. 10.3389/fvets.2019.00383.
- BENNAIM, M., M. PORATO, A. JARLETON, M. HAMON, J. D. CARROLL, K. GOMMEREN, M. BALLIGAND (2017): Preliminary evaluation of the effects of photobiomodulation therapy and physical rehabilitation on early postoperative recovery of dogs undergoing hemilaminectomy for treatment of thoracolumbar intervertebral disk disease. Am. J. Vet. Res. 78, 195–206. 10.2460/ajvr.78.2.195.
- BUSSIÈRES, M. P., S. GRASSO and P. JULL (2024): Preliminary evaluation of an indwelling epidural catheter for repeat methylprednisolone administration in canine lumbosacral stenosis. Can. Vet. J. 65, 462–472.
- DE CASTRO, M. V., M. V. R. DA SILVA, G. B. CHIAROTTO, B. B. VOLPE, M. H. SANTANA, Â. C. MALHEIROS LUZO et al. (2019): Reflex arc recovery after spinal cord dorsal root repair with platelet rich plasma (PRP). Brain Res. Bull. 152, 212–224. 10.1016/j.brainresbull.2019.07.024.
- EVERTS, P., K. ONISHI, P. JAYARAM, J. F. LANA and K. MAUTNER (2020): Platelet-rich plasma: New performance understandings and therapeutic considerations in 2020. Int. J. Mol. Sci. 21, 7794. doi.org/10.3390/ijms21207794.
- HERNÁNDEZ-GUERRA, Á. M., J. M. CARRILLO, J. J. SOPENA, J. M. VILAR, P. PELÁEZ, B. CUERVO et al. (2021): Platelet-rich plasma for the treatment of degenerative lumbosacral stenosis: A study with retired working dogs. Animals 11, 2965. 10.3390/ani11102965.
- LEVINE, G. J., J. M. LEVINE, C. M. BUDKE, S. C. KERWIN, J.

AU, A. VINAYAK et al. (2009): Description and repeatability of a newly developed spinal cord injury scale for dogs. Prev. Vet. Med. 89, 121–127. 10.1016/j.prevetmed.2009.02.016.
- MAYORAL ROJALS, V., C. AMESCUA GARCIA, P. DENEGri, M. A. NARVAEZ TAMAYO and G. VARRASSI (2023): The invasive management of pain: Diagnosis and new treatment options. Cureus 15, e42717. 10.7759/cureus.42717.
- MILLIS, D. and D. LEVINE (2014): Canine rehabilitation and physical therapy. 2nd Ed. Elsevier Inc. ISBN 1437703097.
- PICAZO, R. A., C. ROJO, J. RODRIGUEZ-QUIROS and A. GONZALES-GIL (2024): Current advances in mesenchymal stem cell therapies applied to wounds and skin, eye, and neuromuscular diseases in companion animals. Animals 14, 1363. 10.3390/ani14091363.
- SALARINIA, R., H. R. SADEGHNIA, D. H. ALAMDARI, S. J. HOSEINI, A. MAFINEZHAD and M. HOSSEINI (2017): Platelet rich plasma: Effective treatment for repairing of spinal cord injury in rat. Acta Orthop. Traumatol. Turc. 51, 254–257. 10.1016/j.aott.2017.02.009.
- SHEN, Y. X., Z. H. FAN, J. G. ZHAO and P. ZHANG (2009): The application of platelet-rich plasma may be a novel treatment for central nervous system diseases. Med. Hypotheses 73, 1038–1040. 10.1016/j.mehy.2009.05.021
- VIDAL-NEGREIRA, F., M. GARCÍA-GONZÁLEZ, V. VALIÑO-CULTELLI and A. GONZÁLEZ-CANTALAPIEDRA (2025): Platelet-rich plasma in veterinary orthopedic surgery: A systematic review and quality evaluation on liquid- and gel-based therapies in dogs. Gels 11, 994. 10.3390/gels11120994.
- VIKARTOVSKA, Z., M. KURICOVA, J. FARBAKOVA, T. LIPTAK, D. MUDRONOVA and F. HUMENIK et al. (2020): Stem cell conditioned medium treatment for canine spinal cord injury: Pilot feasibility study. Int. J. Mol. Sci. 21, 5129. 10.3390/ijms21145129.
- WANG, S., Z. LIU, J. WANG, L. CHENG, J. HU and J. TANG (2024): Platelet-rich plasma (PRP) in nerve repair. Regen. Ther. 27, 244–250. 10.1016/j.reth.2024.03.017.
- WORTH, A., B. MEIJ and N. JEFFERY (2019): Canine degenerative lumbosacral stenosis: Prevalence, impact and management strategies. Vet. Med. Res. Rep. 10, 169–183. 10.2147/VMRR.S180448.
- WU, W. S., L. R. CHEN and K. H. CHEN (2025): Platelet-rich plasma (PRP): Molecular mechanisms, actions and clinical applications in human body. Int. J. Mol. Sci. 26, 10804. 10.3390/ijms262110804.
- ZHANG, Z., P. LIU, X. XUE, Z. ZHANG, L. WANG, Y. JIANG et al. (2025): The role of platelet-rich plasma in biomedicine: A comprehensive overview. Science 28, 111705.1016/j.isci.2024.111705.
- ZHENG, C., Q. ZHU, X. LIU, X. HUANG, C. HE, L. JIANG, D. QUAN and X. ZHOU (2013): Effect of platelet-rich plasma (PRP) concentration on proliferation, neurotrophic function and migration of Schwann cells in vitro. J. Tissue Eng. Regen. Med. 10, 428–436. 10.1002/term.1756.
- ZIDAN, N., C. SIMS, J. FENN, K. WILLIAMS, E. GRIFFITH, P. J. EARLY, C. L. MARIANI et al. (2018): A randomized, blinded, prospective clinical trial of postoperative rehabilitation in dogs after surgical decompression of acute thoracolumbar intervertebral disc herniation. J. Vet. Intern. Med. 32, 1133–1144. 10.1111/jvim.15086.

> Epiduralna primjena autologne plazme bogate trombocitima u francuskog buldoga s kroničnim poremećajem funkcije kralježnične moždine povezanim s malformacijama kralježaka: prikaz slučaja

Bianca PEHAR, drbiancapehar@gmail.com, orcid.org/0009-0007-7160-0934; Hrvoje MILOŠEVIĆ, hrvoje.milosevic@vfs.unsa.ba, orcid.org/0000-0003-4625-5888; Muamer OBHOĐAŠ, muamer.obhodjas@vfs.unsa. ba, orcid.org/0000-0001-7489-4279; Alan MAKSIMOVIĆ* (dopisni autor), alan.maksimovic@vfs.unsa.ba, orcid.org/0000-0002-4127-9445.

Katedra za kliničke nauke veterinarske medicine, Veterinarski fakultet Univerziteta u Sarajevu, 71000 Sarajevo, Bosna i Hercegovina

Plazma bogata trombocitima (PRP), autologni krvni pripravak obogaćen čimbenicima rasta, potiče regeneraciju tkiva, smanjuje upalu i doprinosi obnovi živčanog tkiva. Iako se široko primjenjuje u ortopediji, njezina epiduralna primjena u liječenju poremećaja funkcije kralježnične moždine u pasa još uvijek je nedovoljno istražena. U ovom prikazu slučaja opisana je osmogodišnja ovariohisterektomizirana kuja pasmine francuski buldog s progresivnom paraparezom, proprioceptivnim deficitima te urinarnom i fekalnom inkontinencijom. Magnetskom rezonancijom (MRI) i računalnom tomografijom (CT) utvrđene su malformacije kralježaka, vjerojatni arahnoidalni divertikul i kompresija kralježnične moždine. Primjena kortikosteroida rezultirala je privremenim kliničkim poboljšanjem, nakon čega je tijekom postupnog smanjivanja doze došlo do ponovnog pogoršanja kliničkog stanja. PRP je primijenjen epiduralno 0., 15., 30. i 45. dana, a pripravljen je postupkom centrifugiranja u dva koraka. Postupak je dobro podnesen, bez potrebe za sedacijom ili anestezijom. Zabilježeno je poboljšanje neurološkog statusa, uključujući ponovnu uspostavu sposobnosti samostalnog kretanja i smanjenje proprioceptivnih deficita, što je procijenjeno primjenom Teksaške ljestvice za procjenu ozljede kralježnične moždine (Texas Spinal Cord Injury Scale). Ovi nalazi upućuju na to da bi epiduralna primjena PRP-a mogla predstavljati sigurnu, minimalno invazivnu i obećavajuću dodatnu terapijsku metodu u liječenju poremećaja funkcije kralježnične moždine u pasa.

Ključne riječi: *plazma bogata trombocitima; epiduralna terapija; poremećaj funkcije kralježnične moždine; pas; neurološki oporavak.*